

Classification and Management of the Unstable Total Hip Arthroplasty

Esetbemutatók

Glenn D. Wera, MD,* Nick T. Ting, MD,† Mario Moric, MS,‡
Wayne G. Paprosky, MD,† Scott M. Sporer, MD,† and Craig J. Della Valle, MD†

The Journal of Arthroplasty 37 (2022) 993–1001



Contents lists available at ScienceDirect

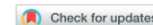The Journal of Arthroplasty

journal homepage: www.arthroplastyjournal.org



Systematic Review and Meta-Analysis

The Incidence and Temporal Trends of Dislocation After the Use of Constrained Acetabular Components and Dual Mobility Implants in Primary Total Hip Replacements: A Systematic Review and Meta-Analysis of Longitudinal Observational Studies



Richard L. Donovan, MBBS, MRCS, MSc, MACadMed^{a,b,*}, Harvey Johnson^b,
Sherwin Fernando, MBBS^b, Michael Foxall-Smith, MBBS^b,
Michael R. Whitehouse, MBChB, MSc, PhD, FRCS (Tr&Orth), FHEA^{a,b,c},
Ashley W. Blom, MBChB, MD, PhD, FRCS (Tr&Orth), FMedSci^{a,b,c},
Setor K. Kunutsor, MBChB, MPhil, PhD^{a,c}

Vermes Csaba



Arthroplasty Today 13 (2022) 8–12

PTE, KK, Ortopédiai Klinika

Contents lists available at ScienceDirect



Arthroplasty Today

journal homepage: <http://www.arthroplastytoday.org/>



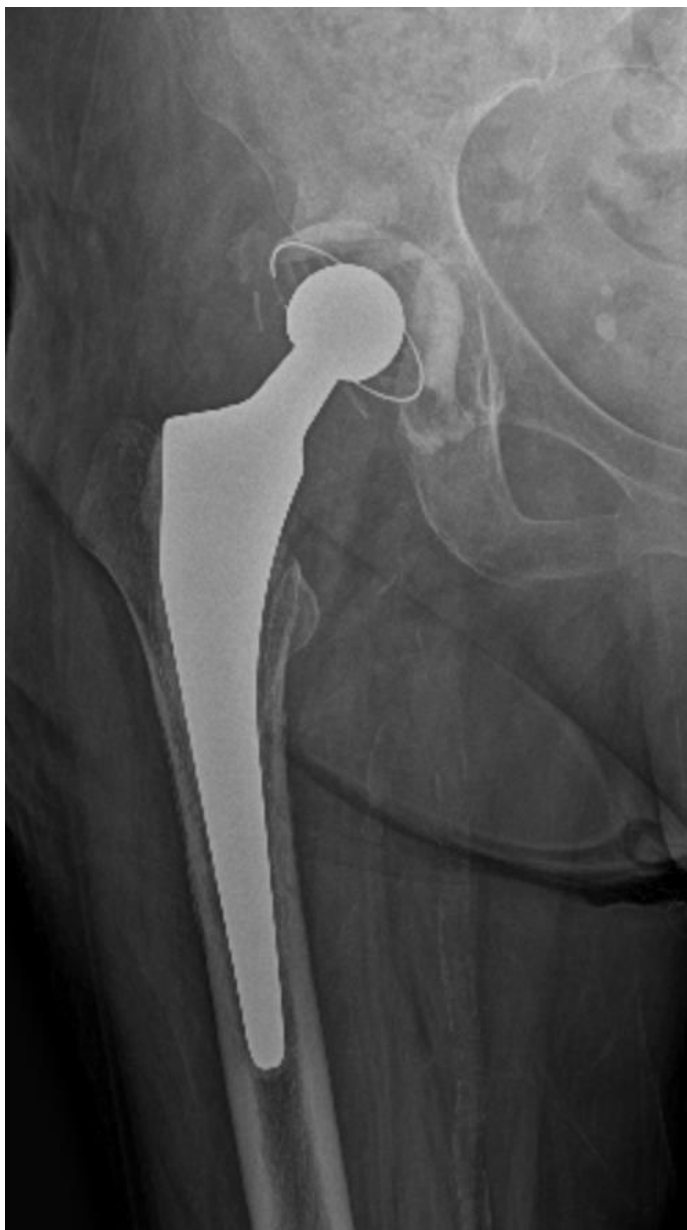Original research

Dual-Mobility Implants and Constrained Liners in Revision Total Hip Arthroplasty

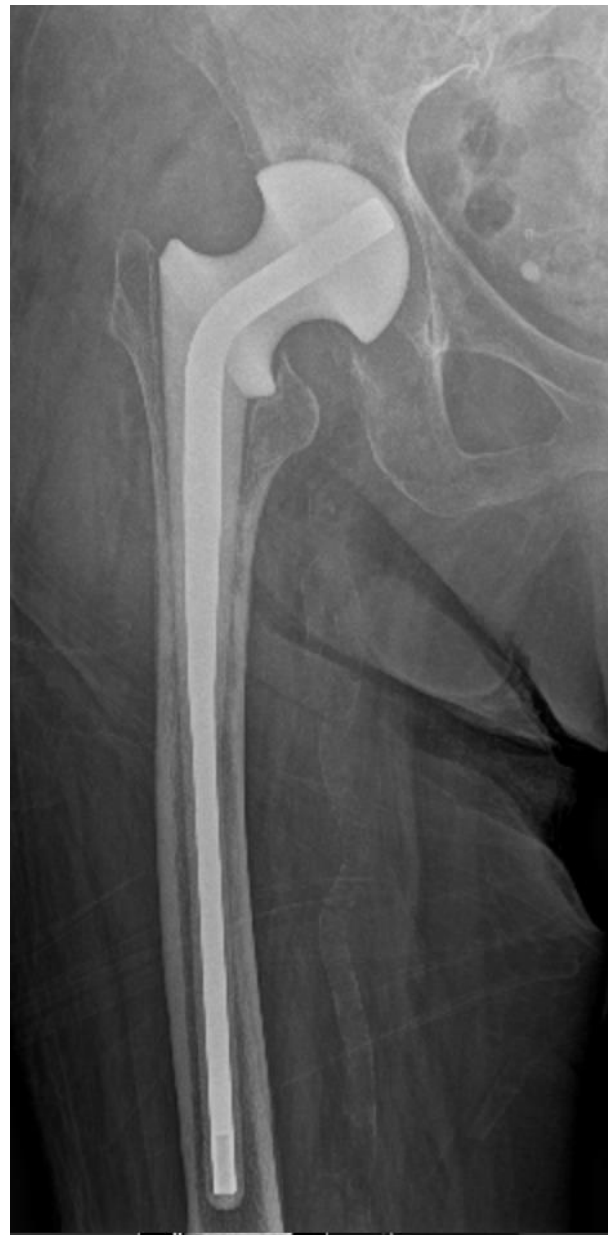Emanuele Chisari, MD, Blair Ashley, MD, Ryan Sutton, MD, Garrett Largoza, BS,
Marco Di Spagna, BS, Nitin Goyal, MD, P Maxwell Courtney, MD, Javad Parvizi, MD*

Rothman Orthopaedic Institute at Thomas Jefferson University, Philadelphia, PA, USA

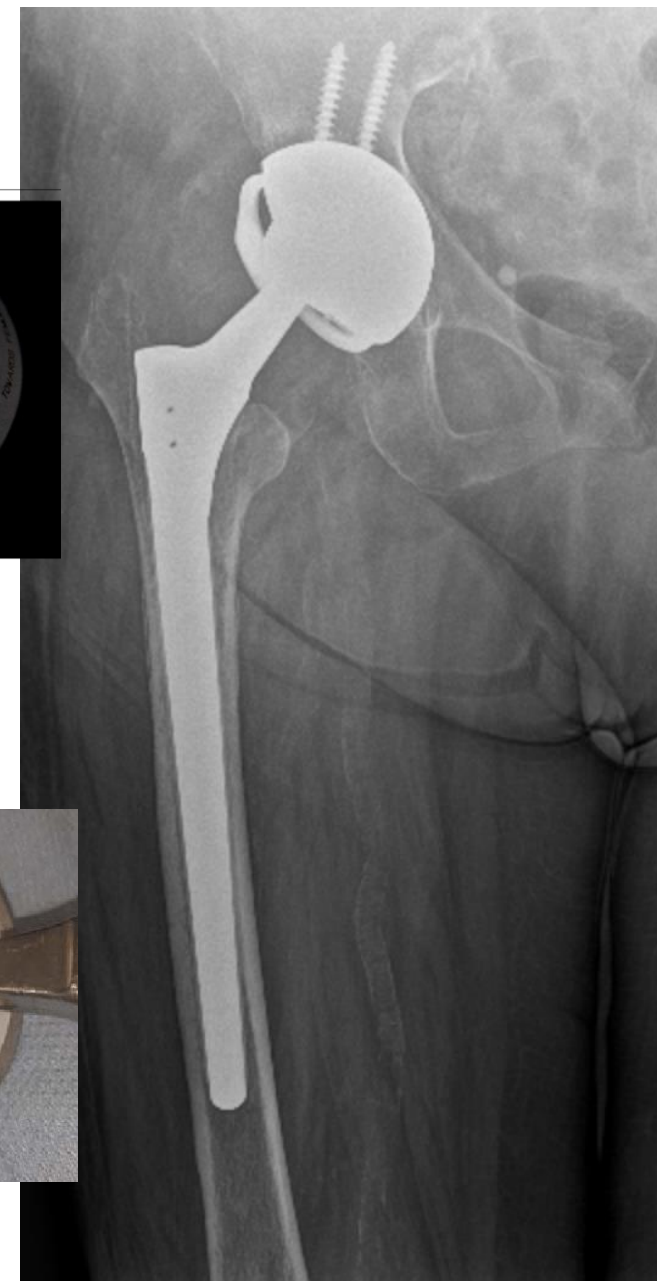
74 éves nő PJI



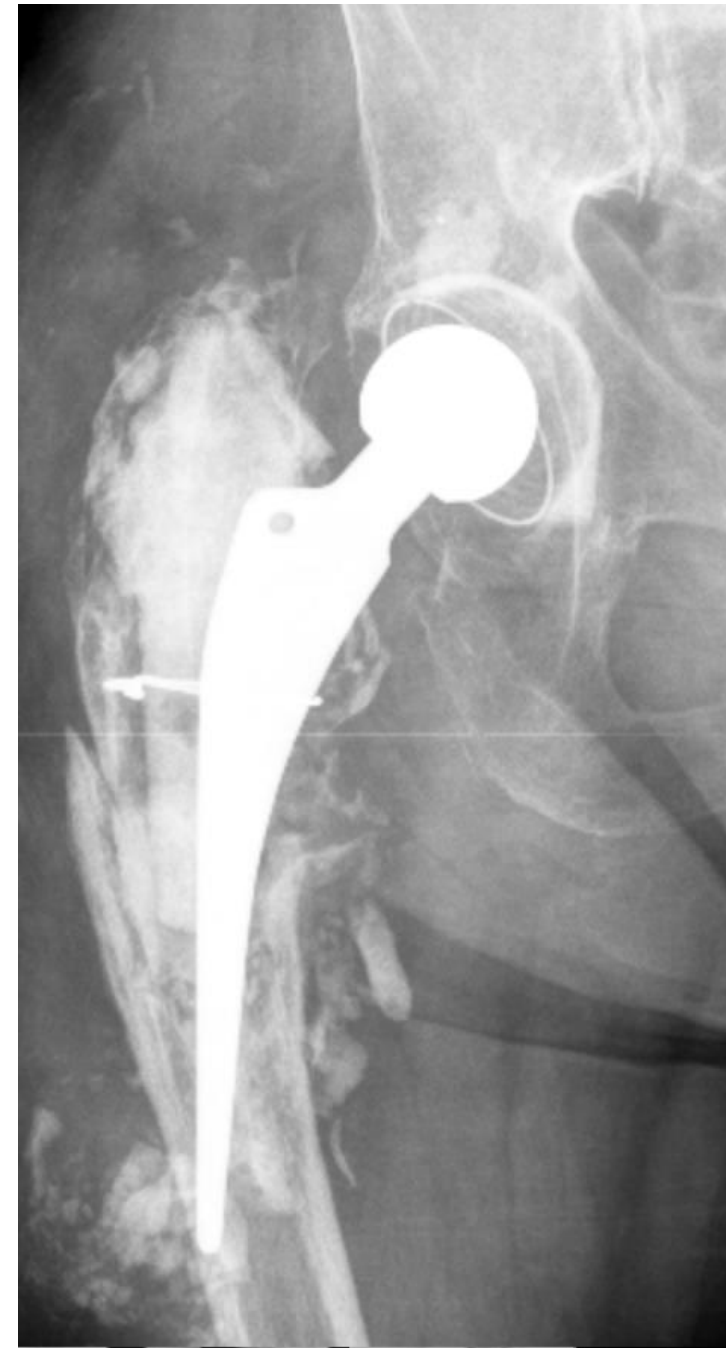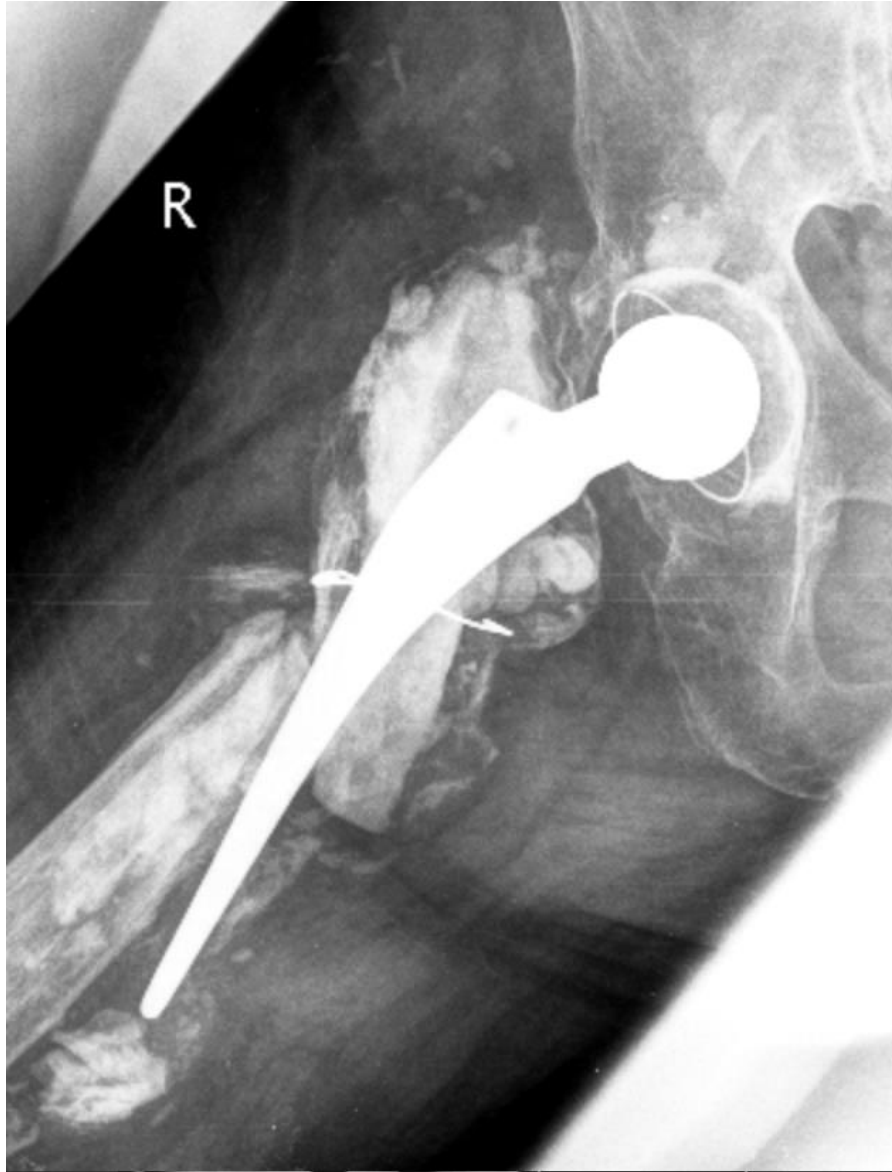PJI, 2 hó postop



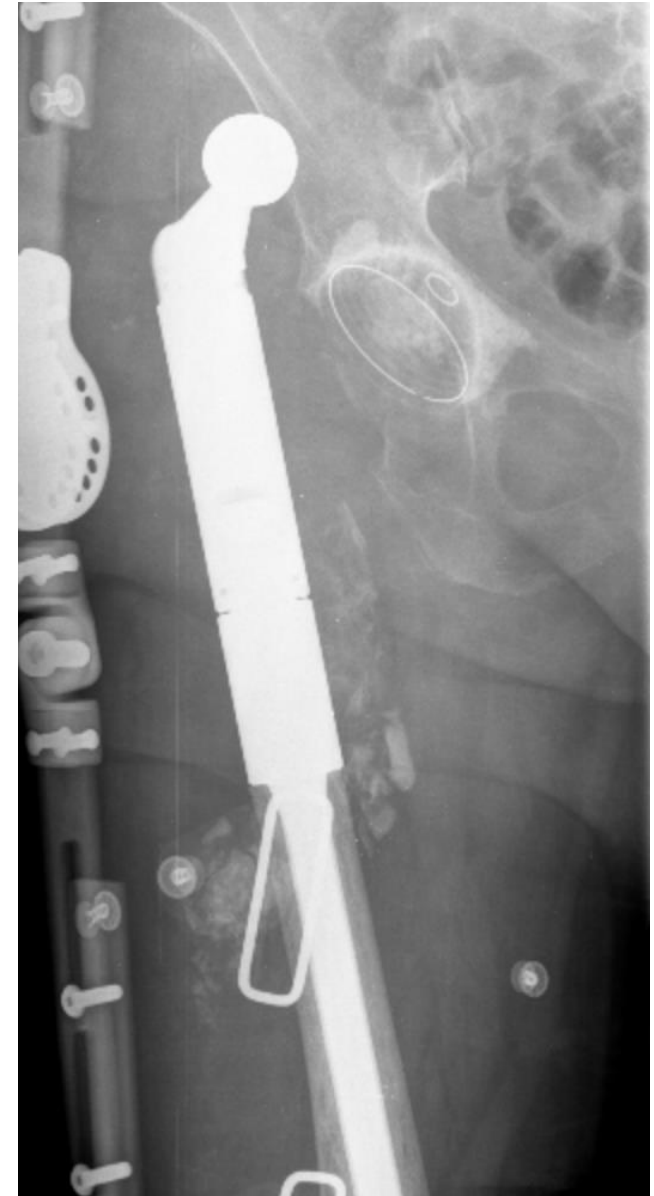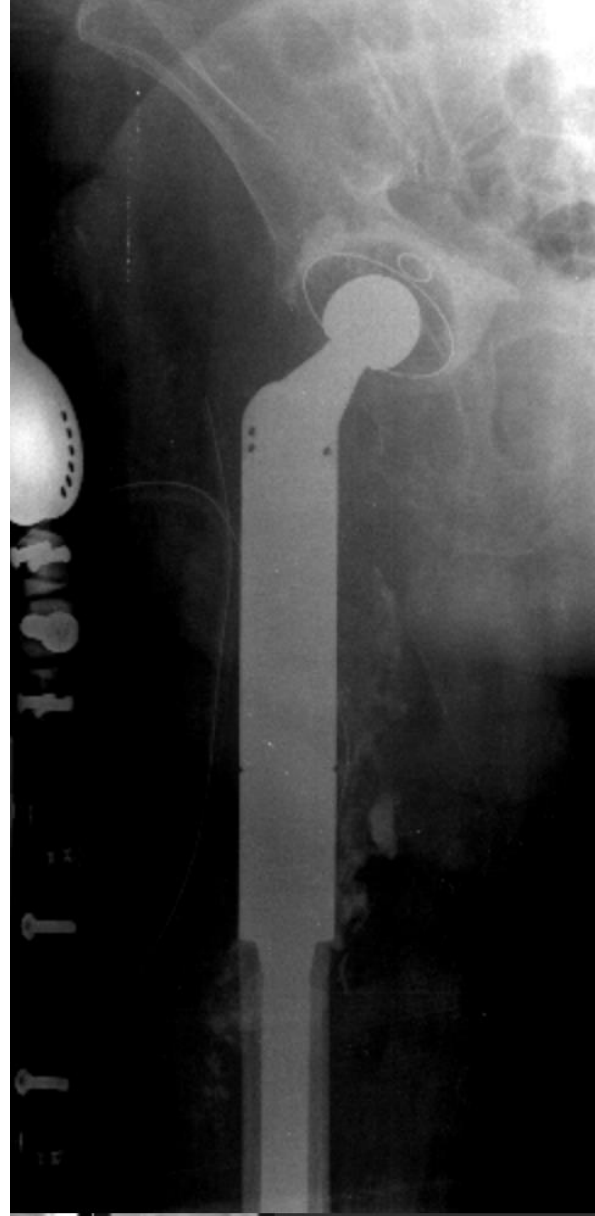2 év postop reimplant



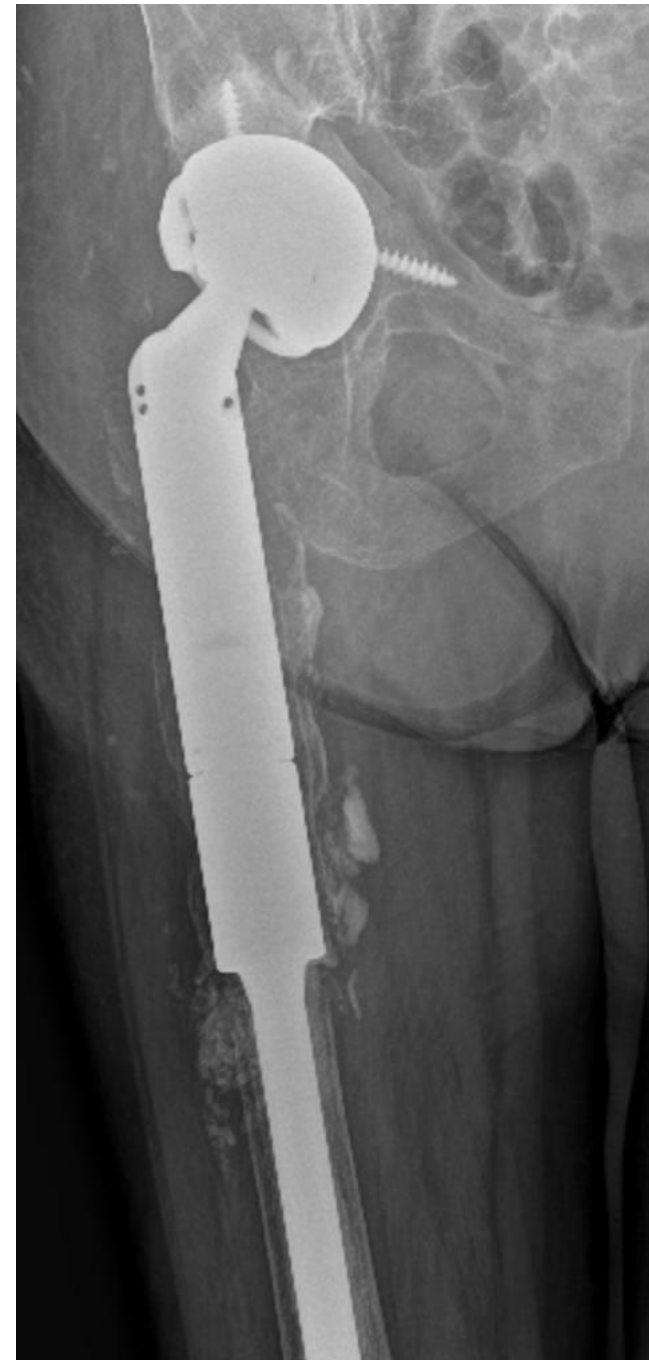77 éves nő, korábban revízió



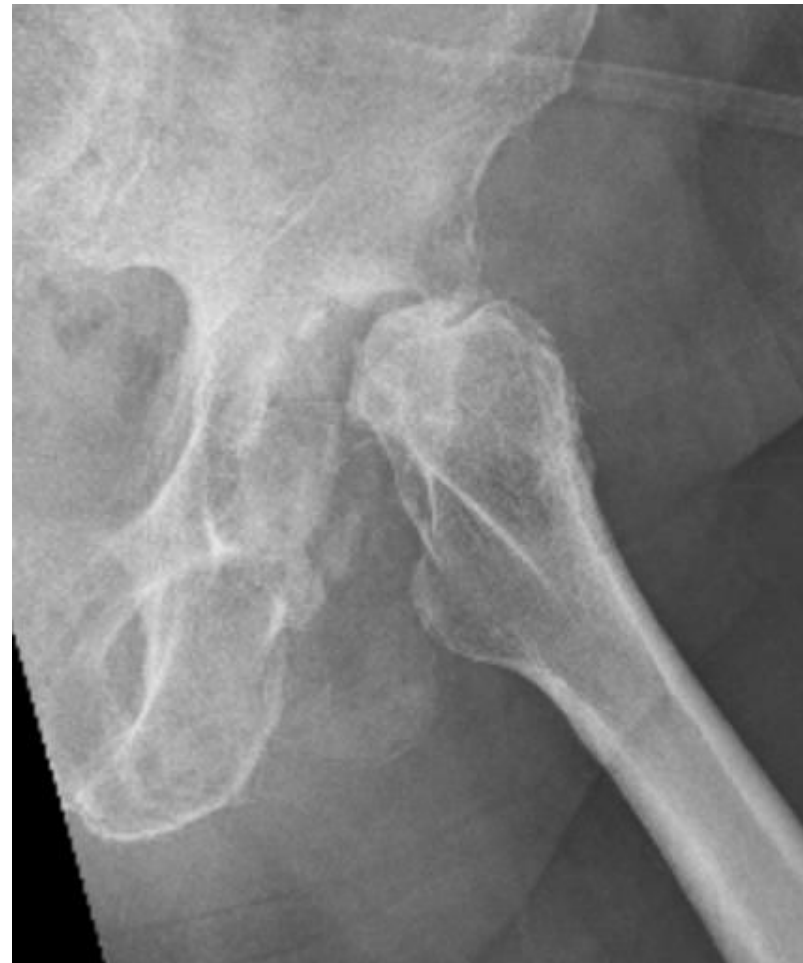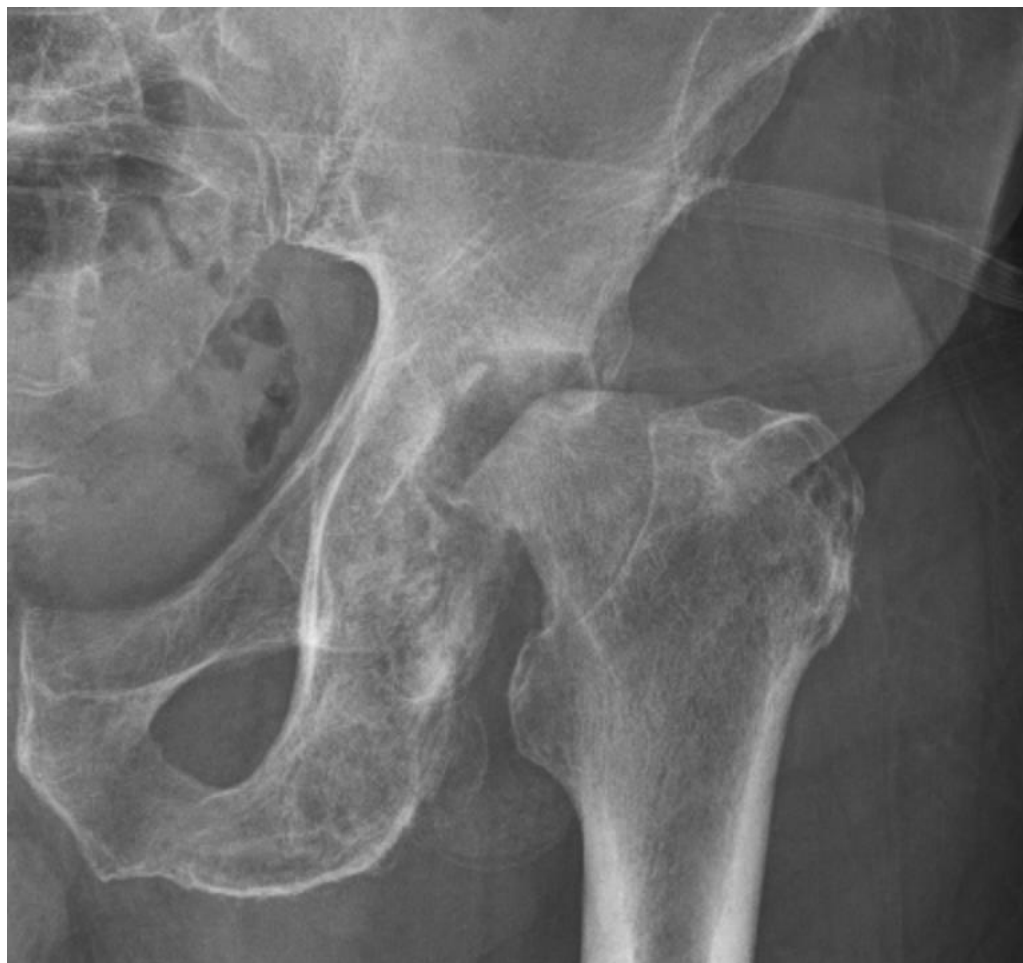Szegmentális-moduláris szár- cementezett vápa-fej 28



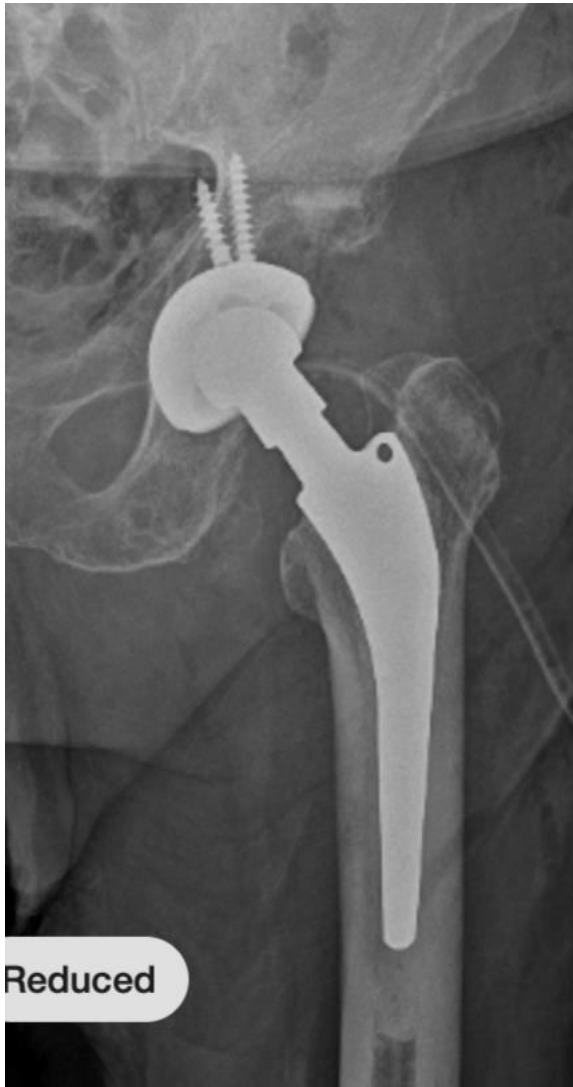Szegmentális-moduláris szár + constrained vápa



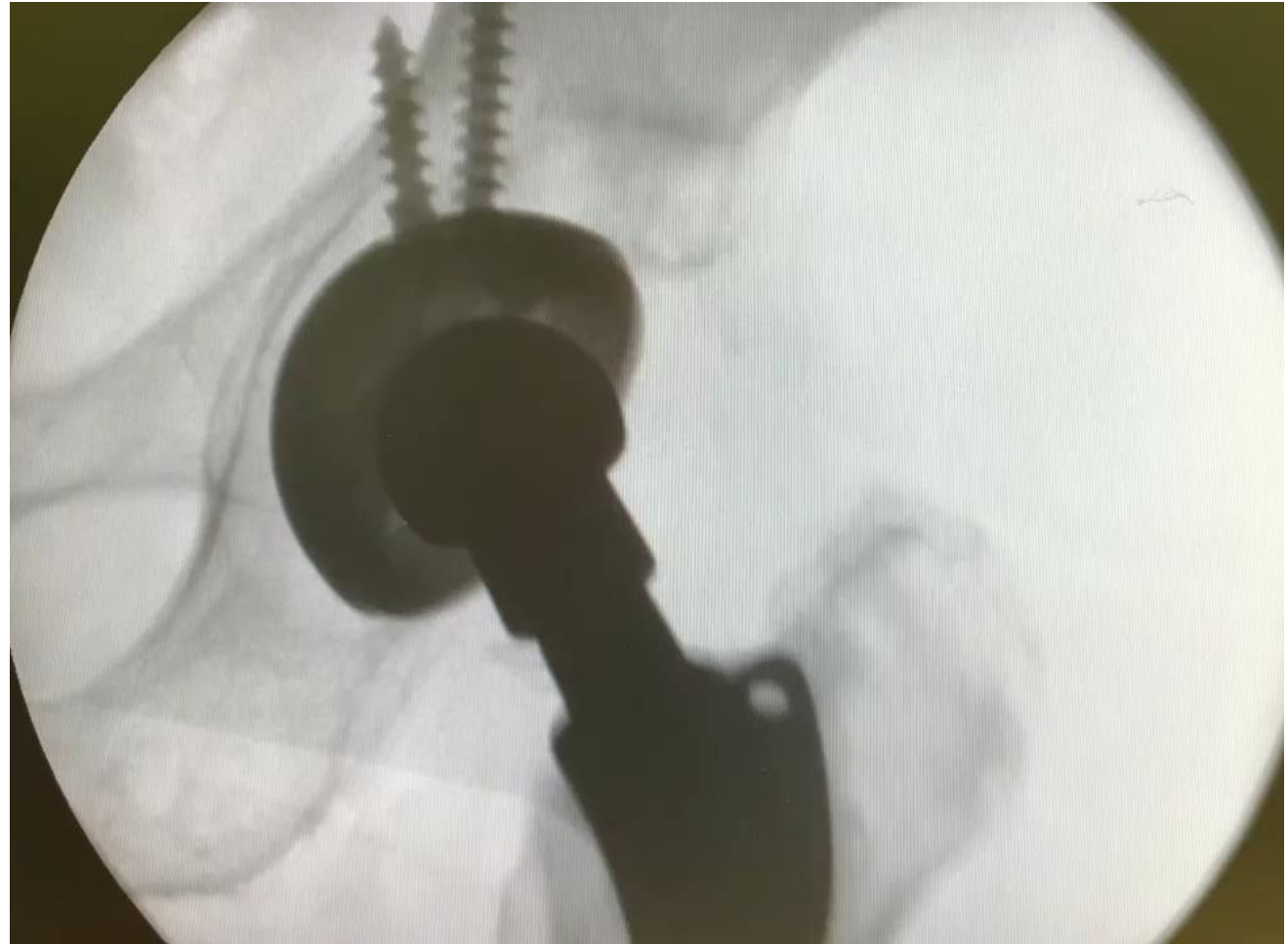
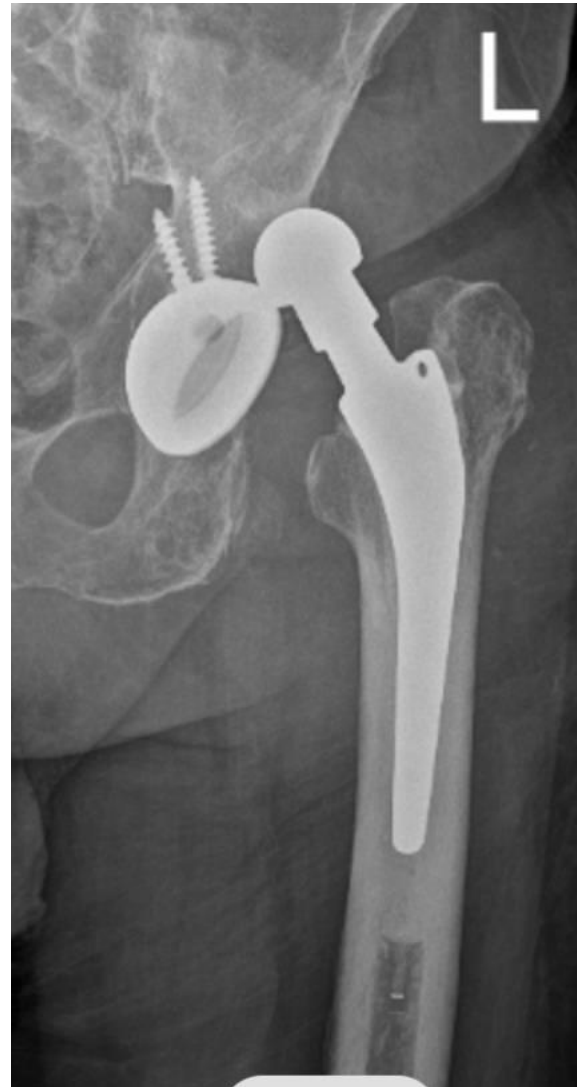74 éves férfi, preop RTG



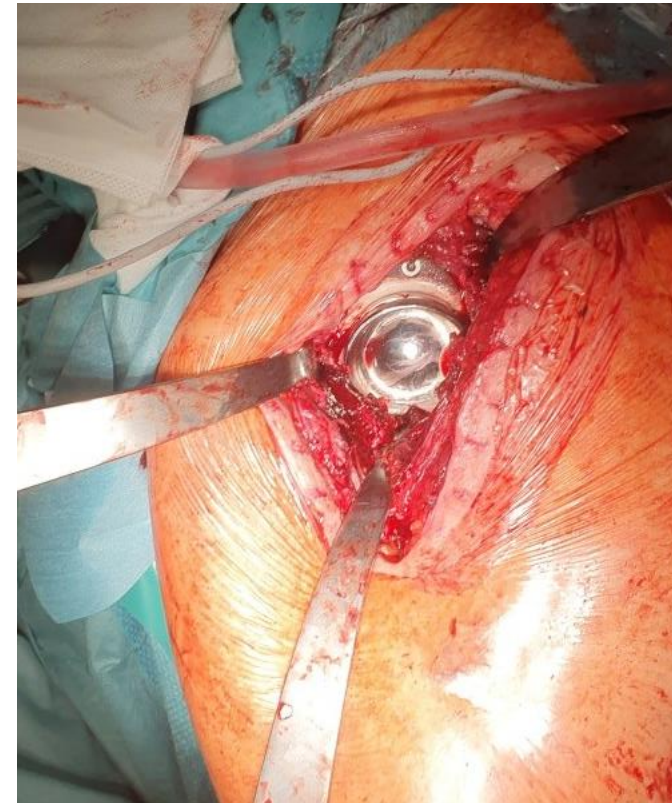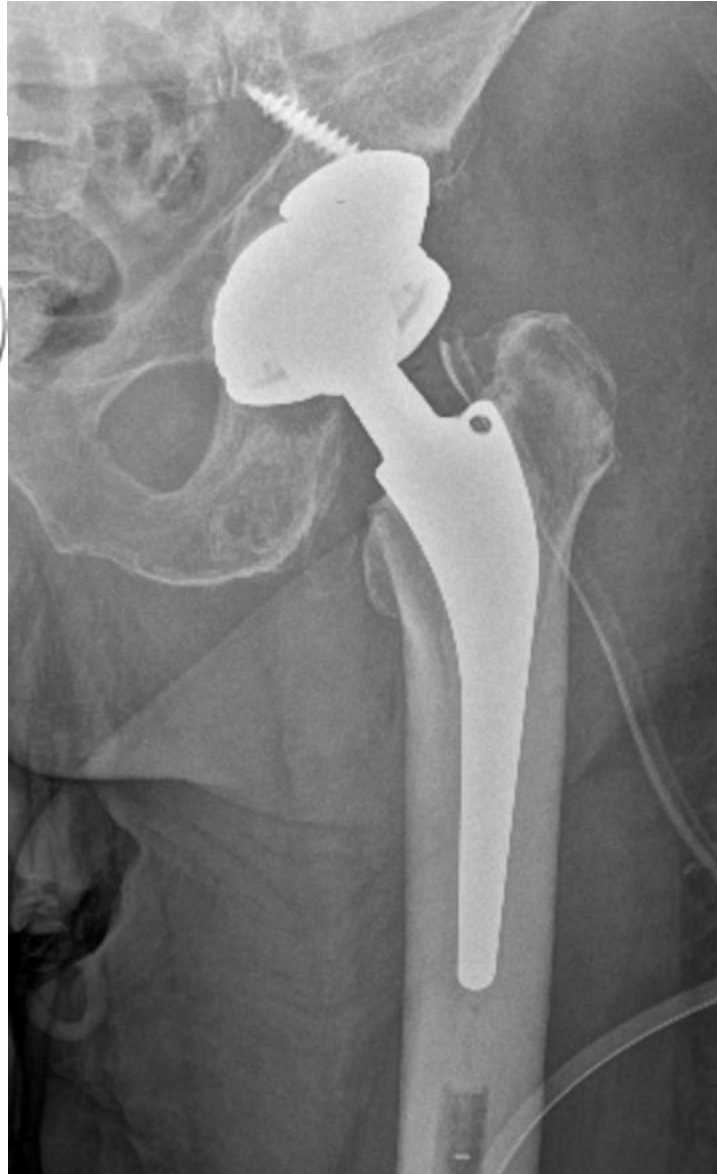Postop RTG



Postop 10. nap

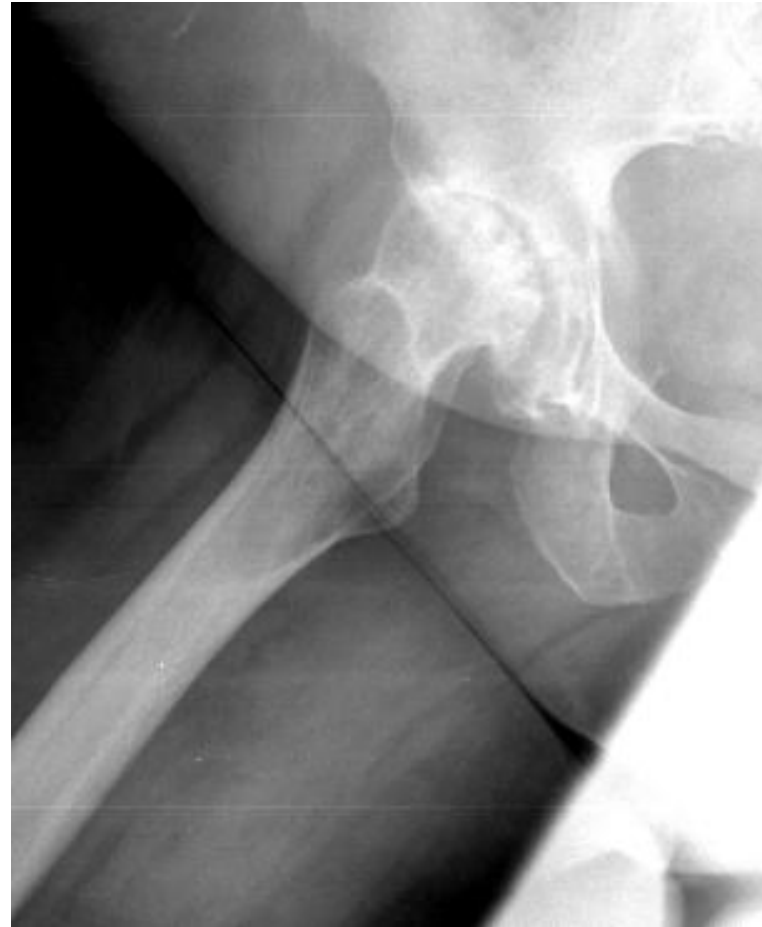
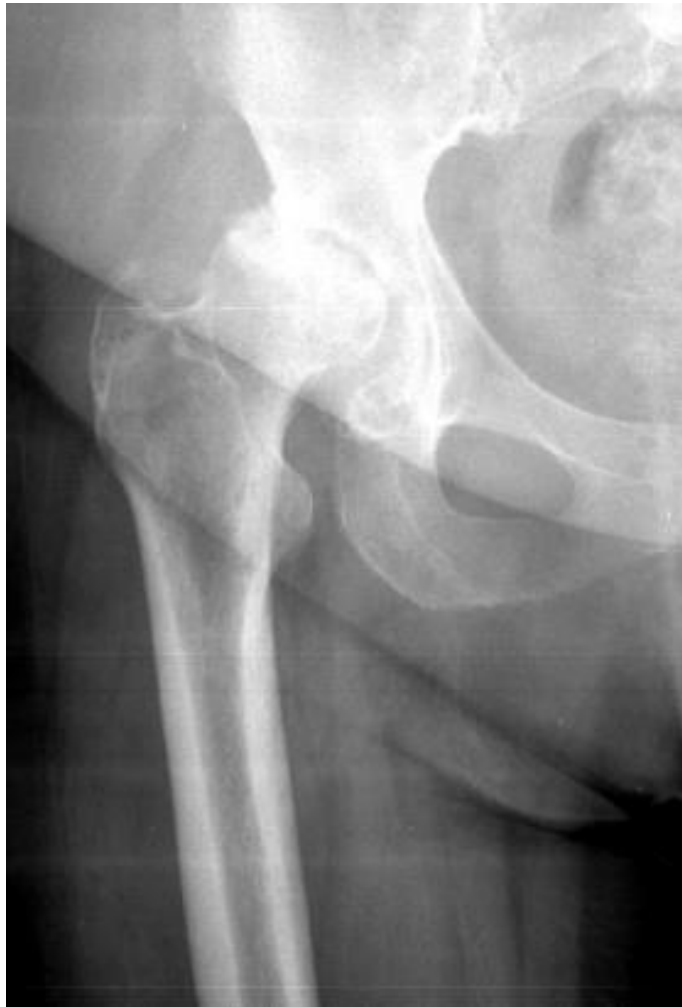
TMARS augment+DM vápa



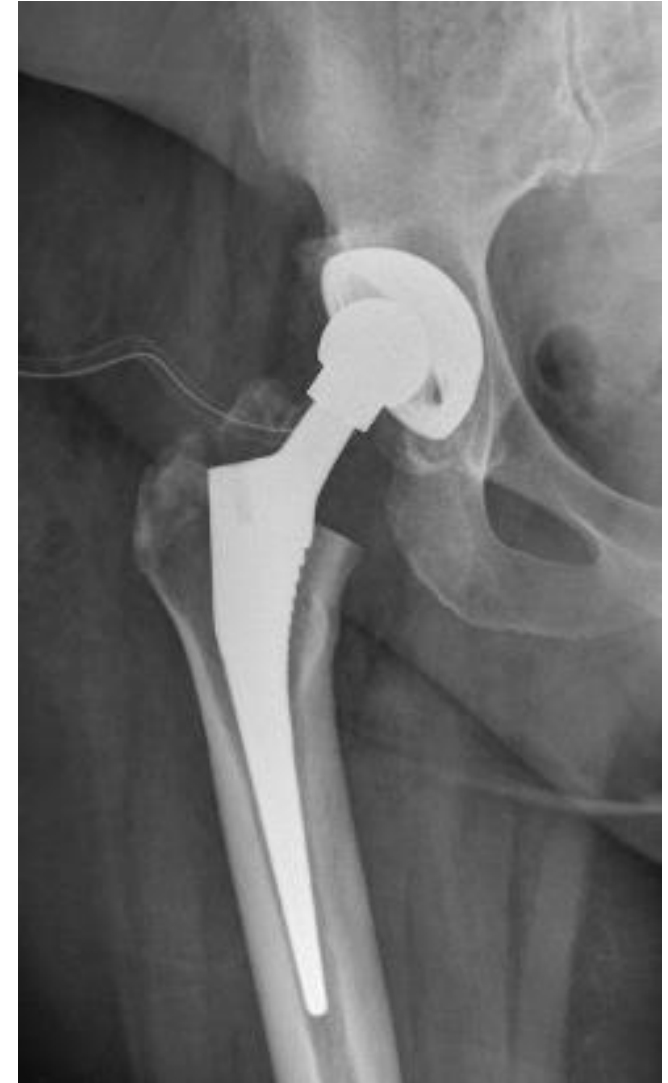64 éves nő (1952.12.20.)

2016.11.21. preop

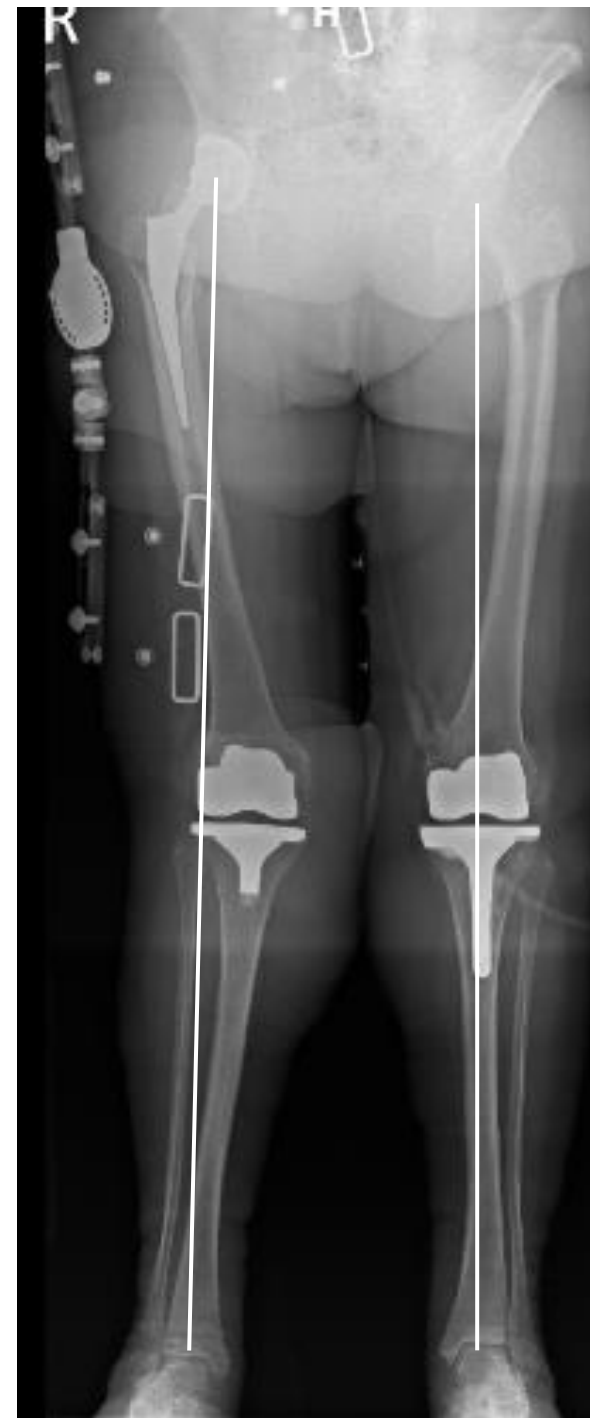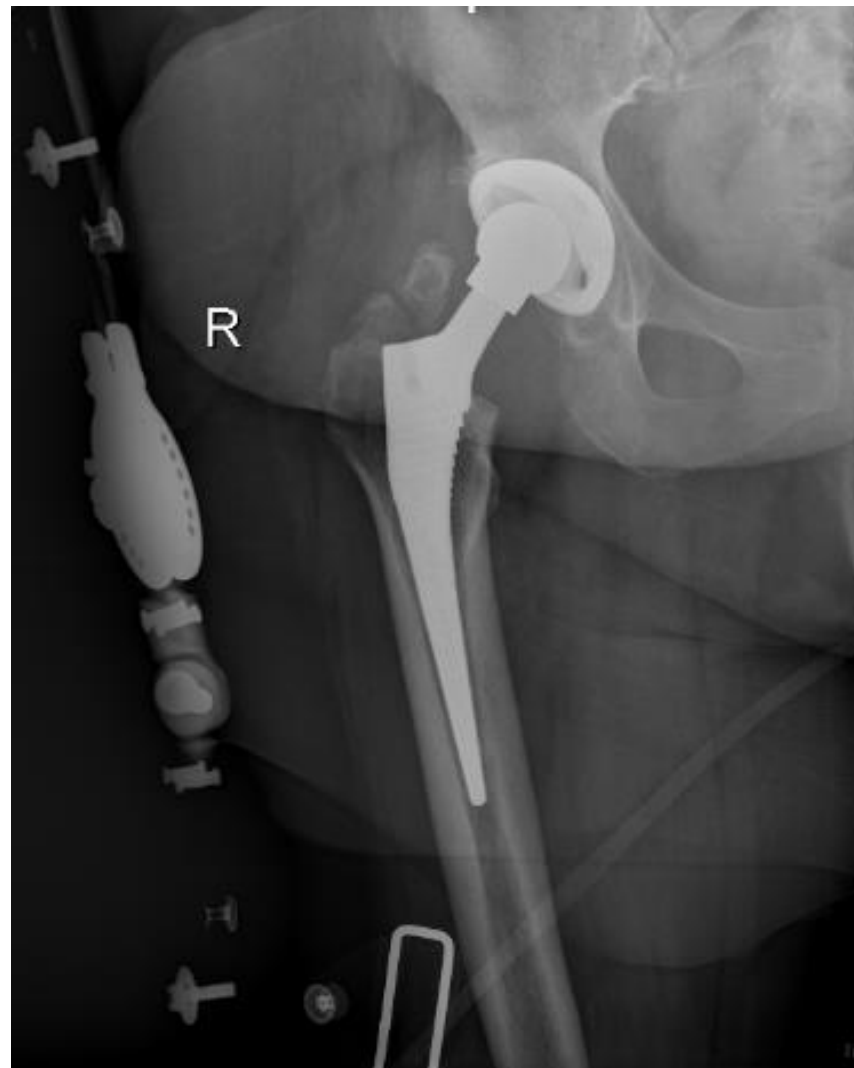

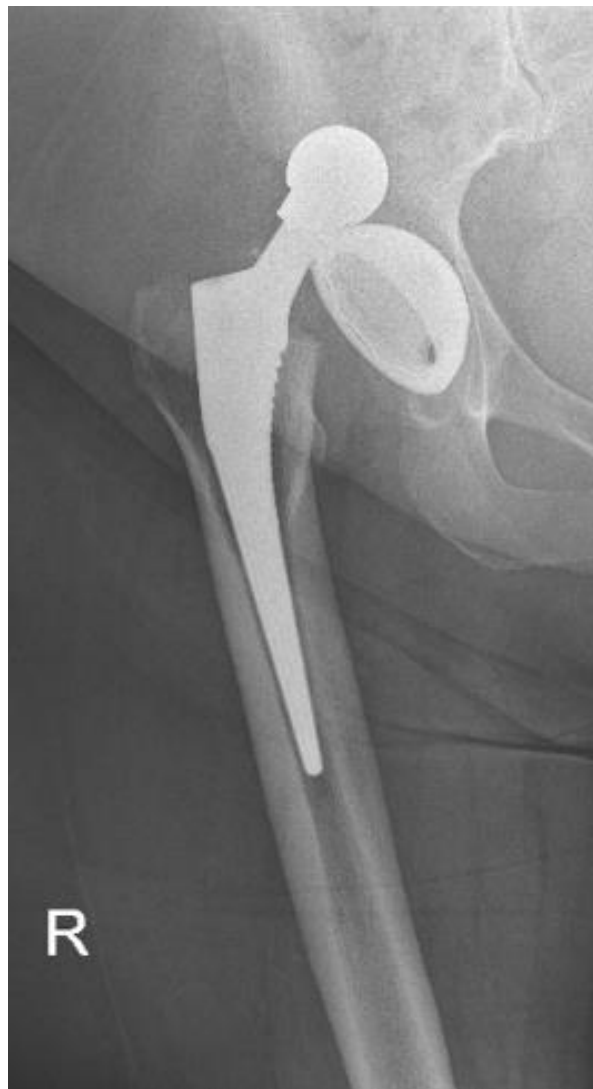
2017.05.04.

postop



2017.06.29.



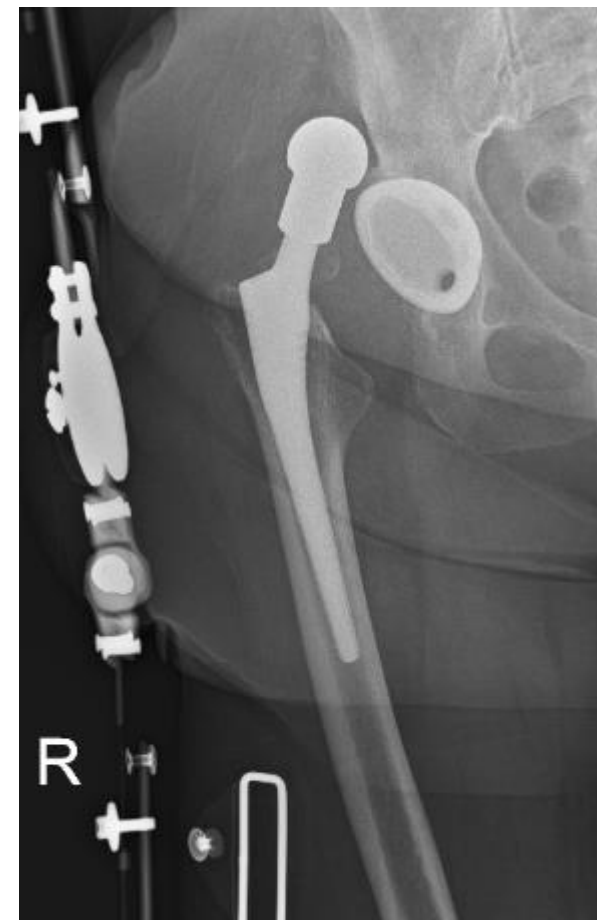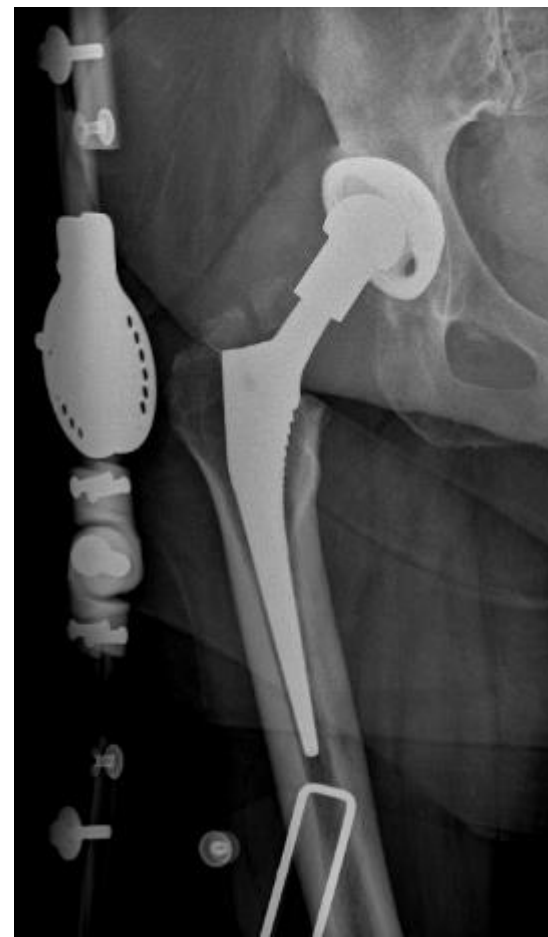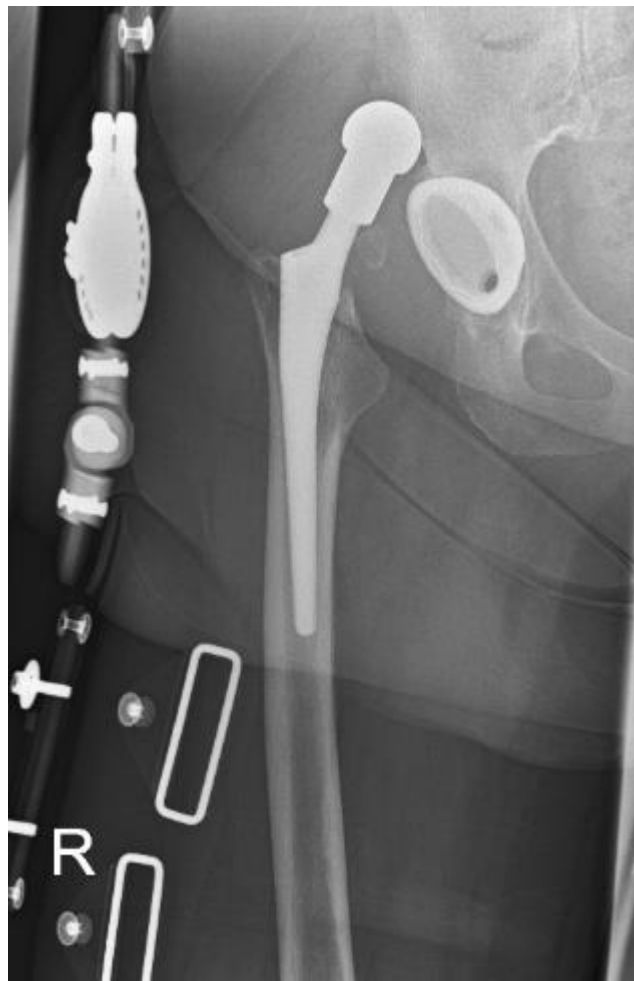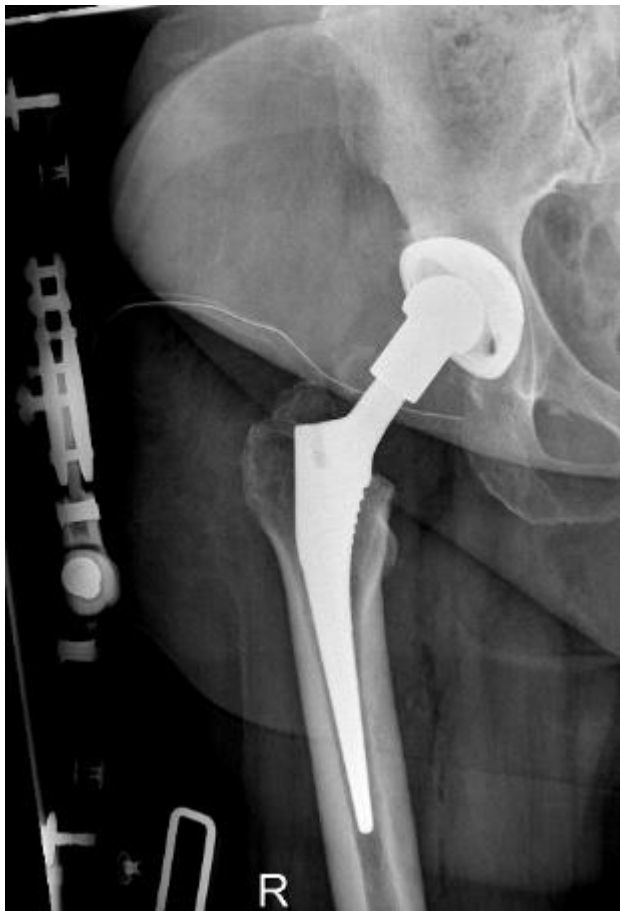2017.11.20

fejcsere

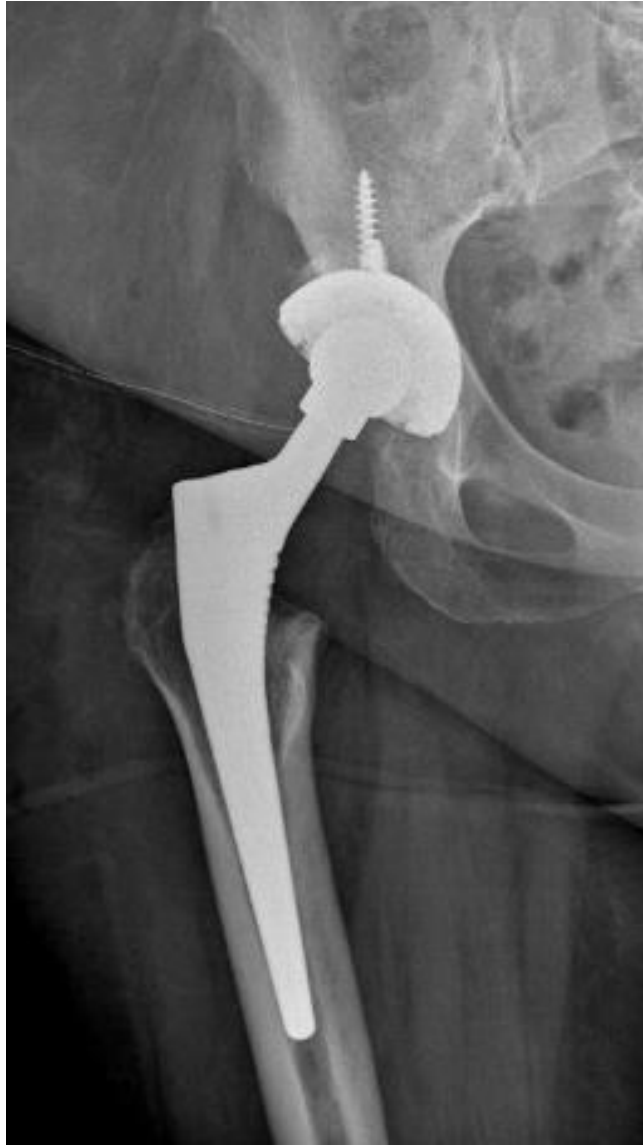2017.12.08.

2017.12.11.

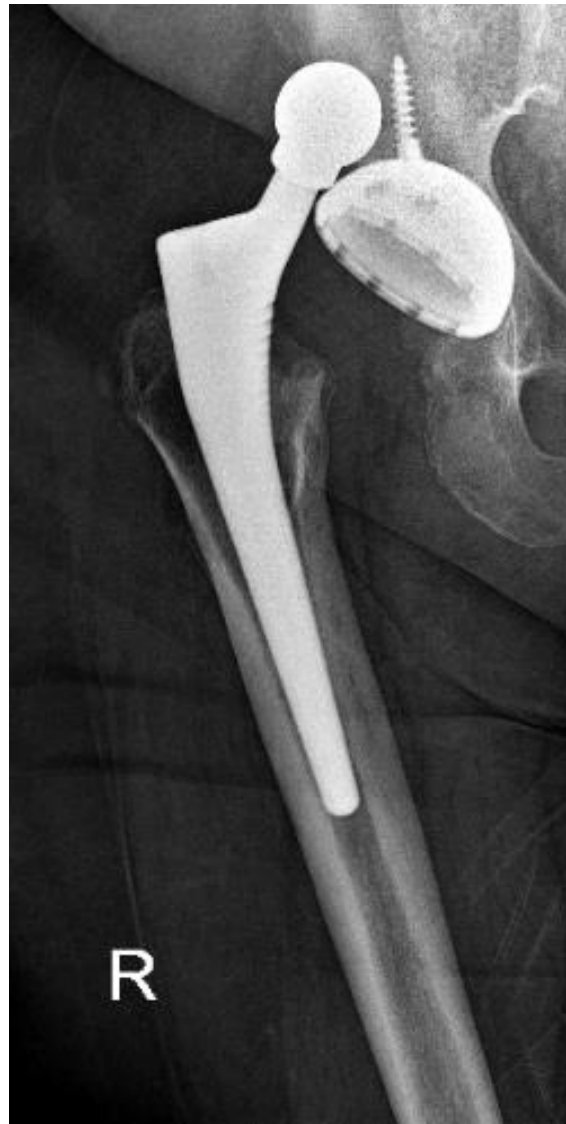2017.12.31.



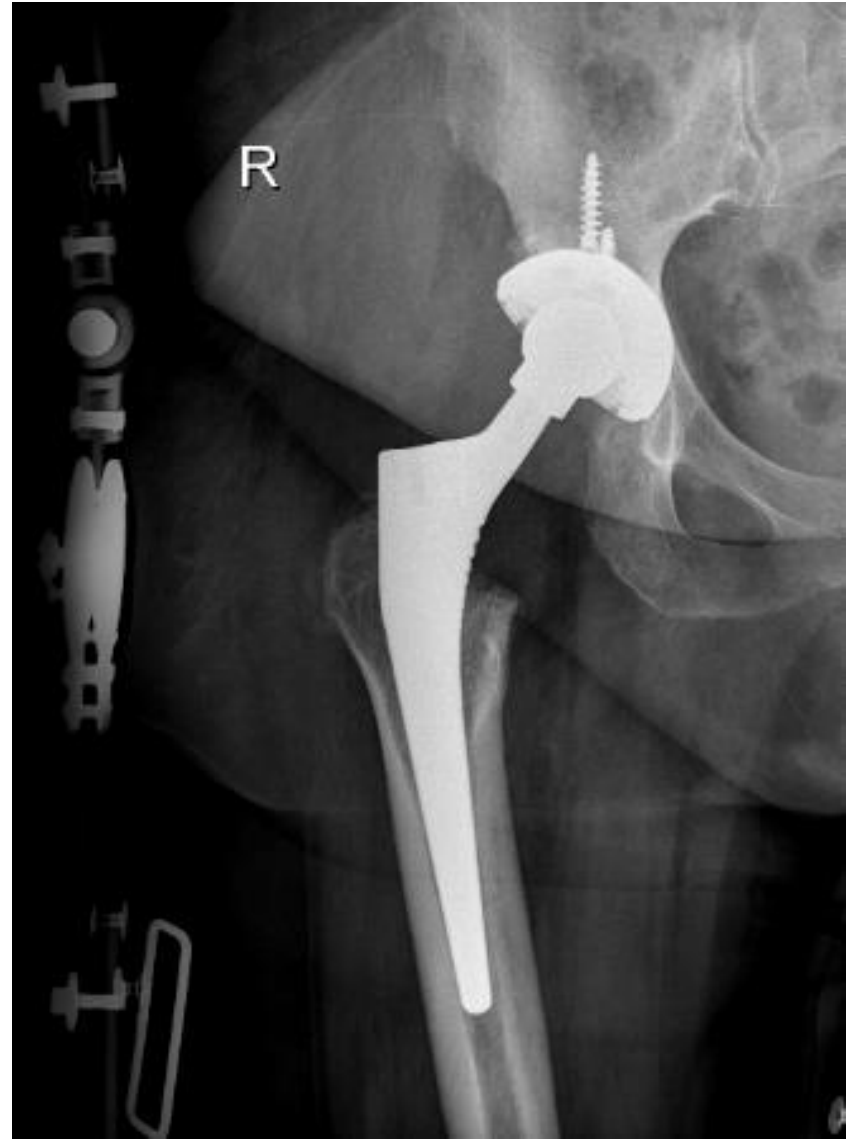2018.01.04.-reop



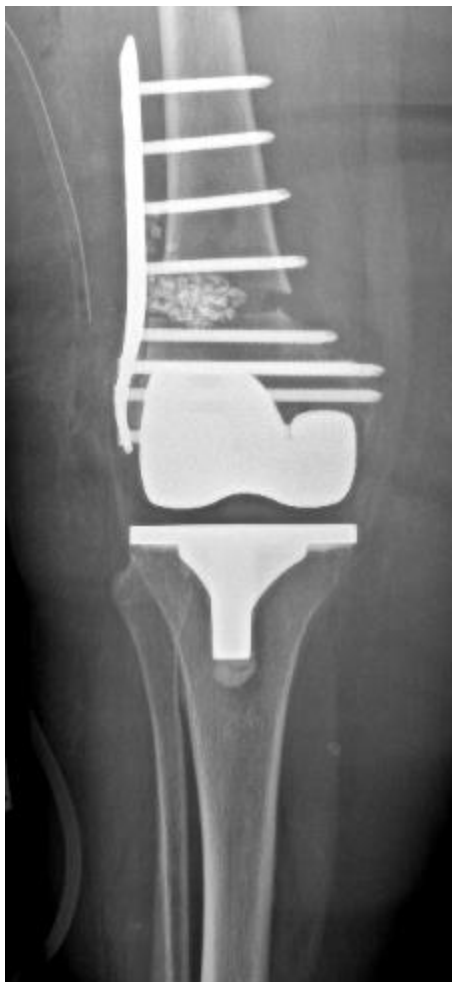2018.02.20



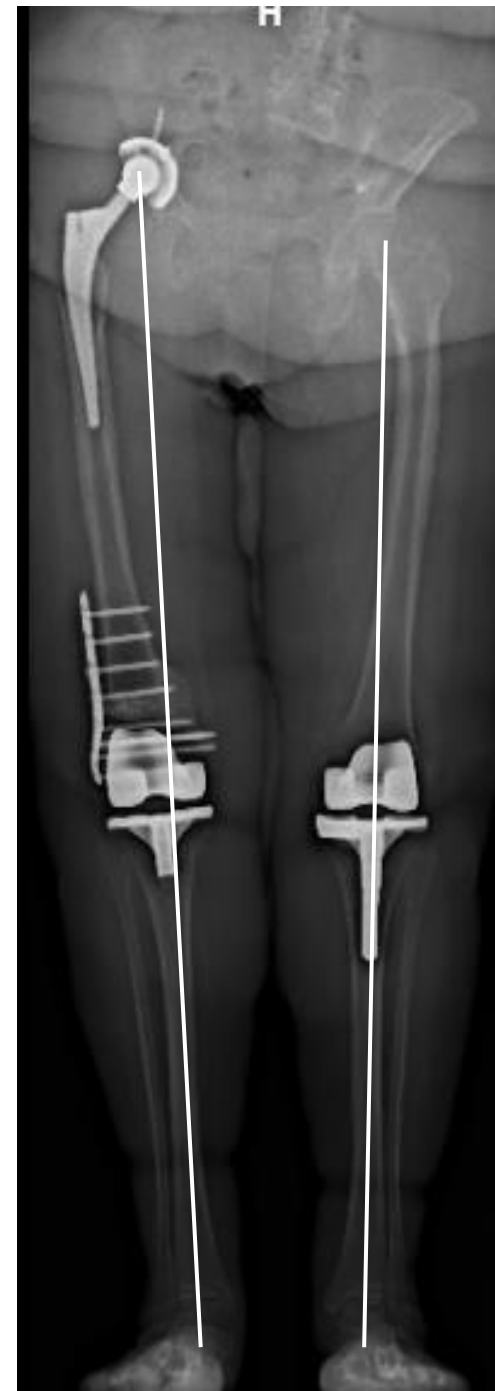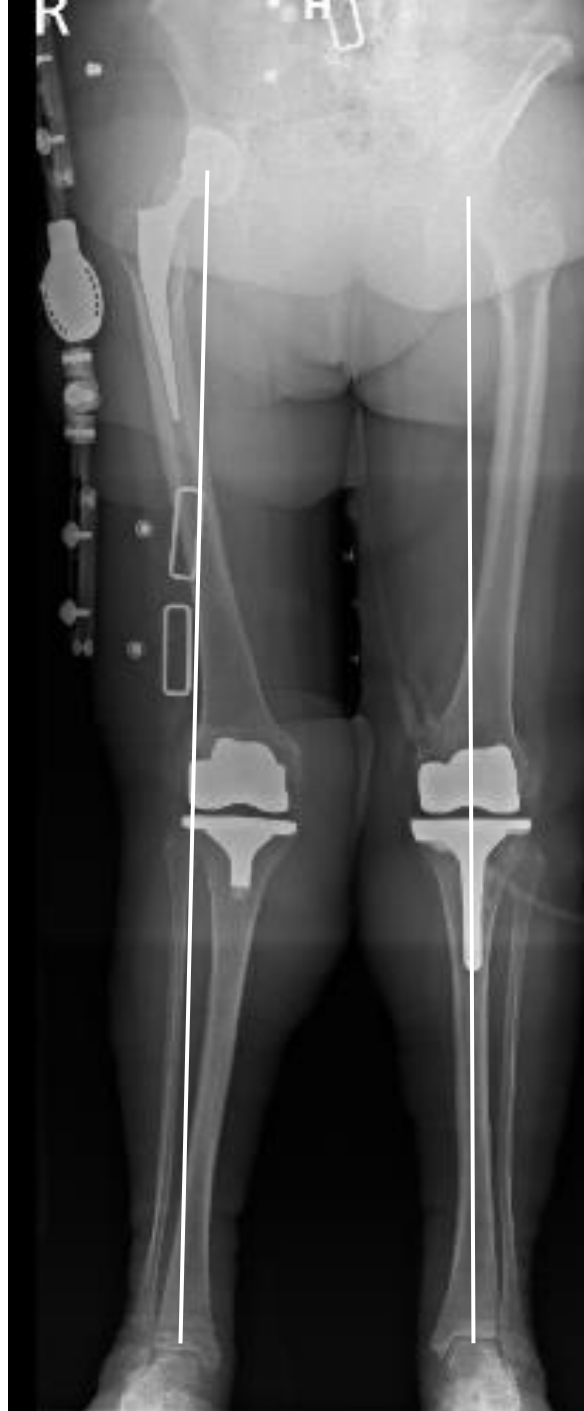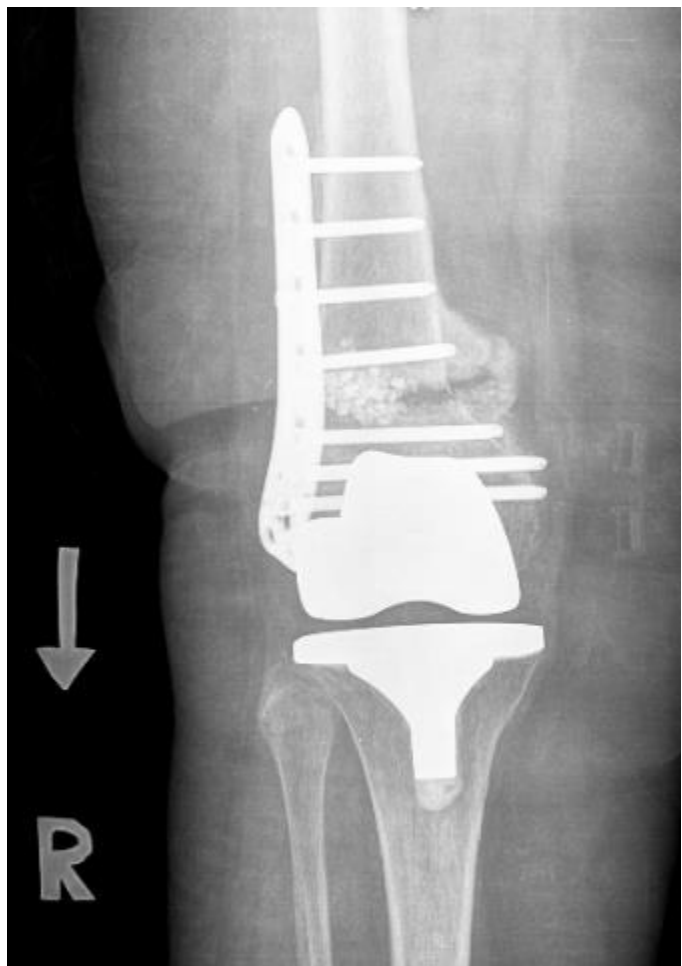2018.02.21.



2018.05.28.

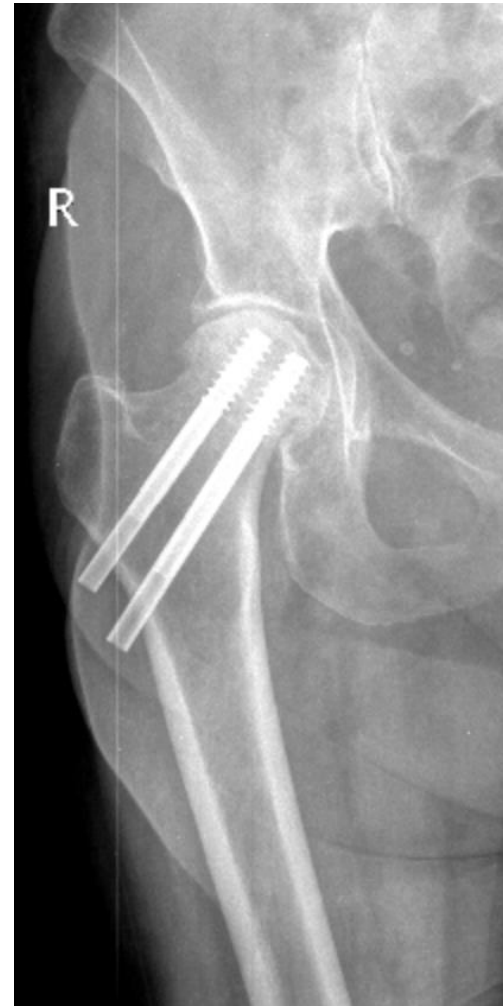
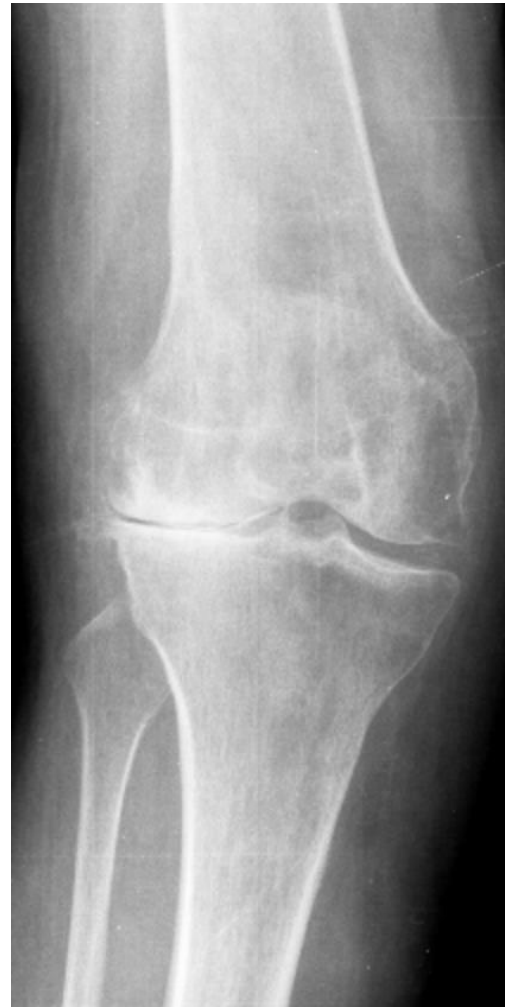
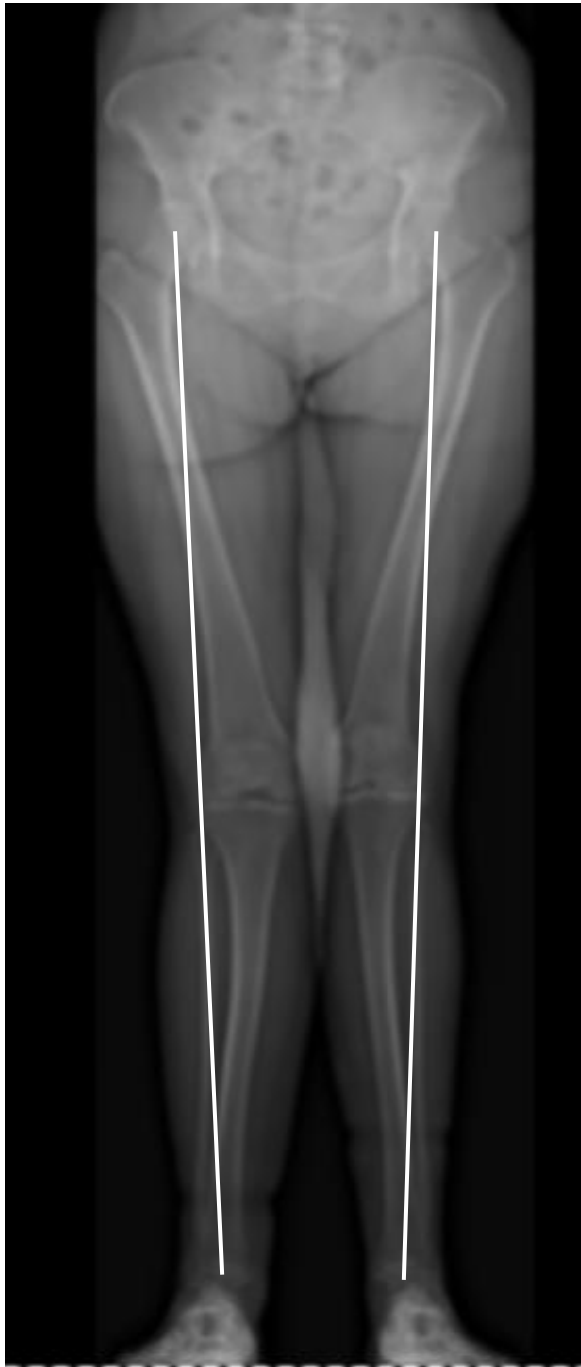2018.09.10

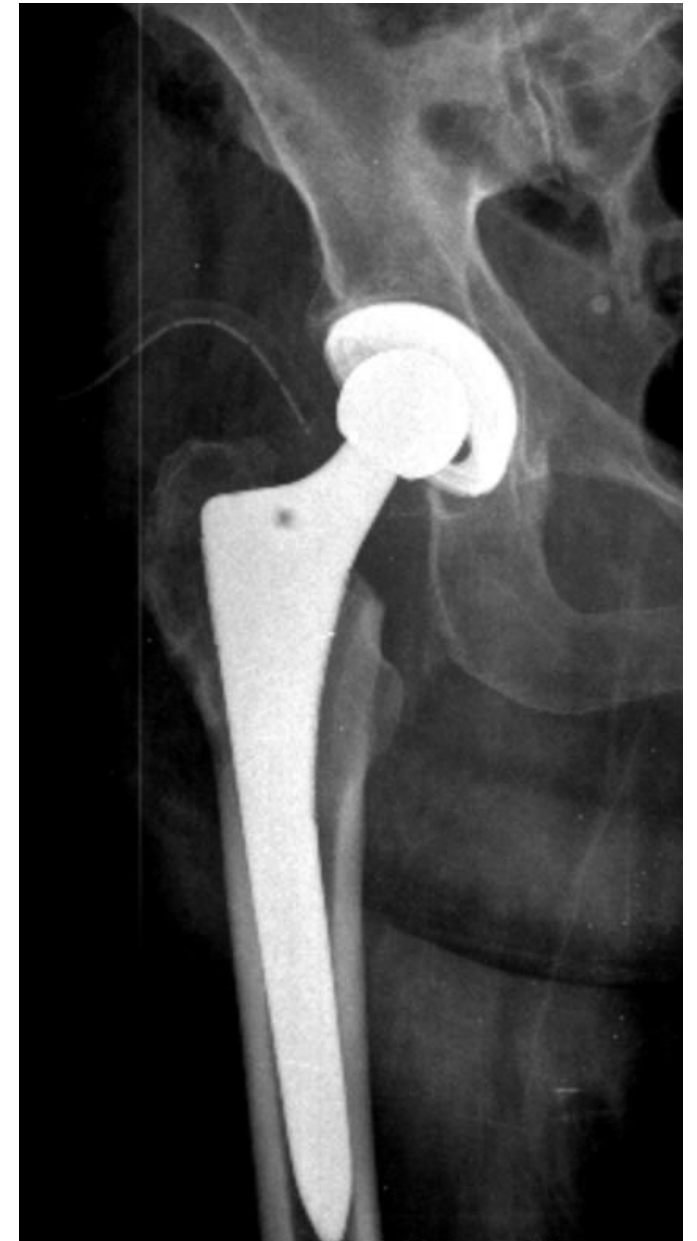

61 éves nő

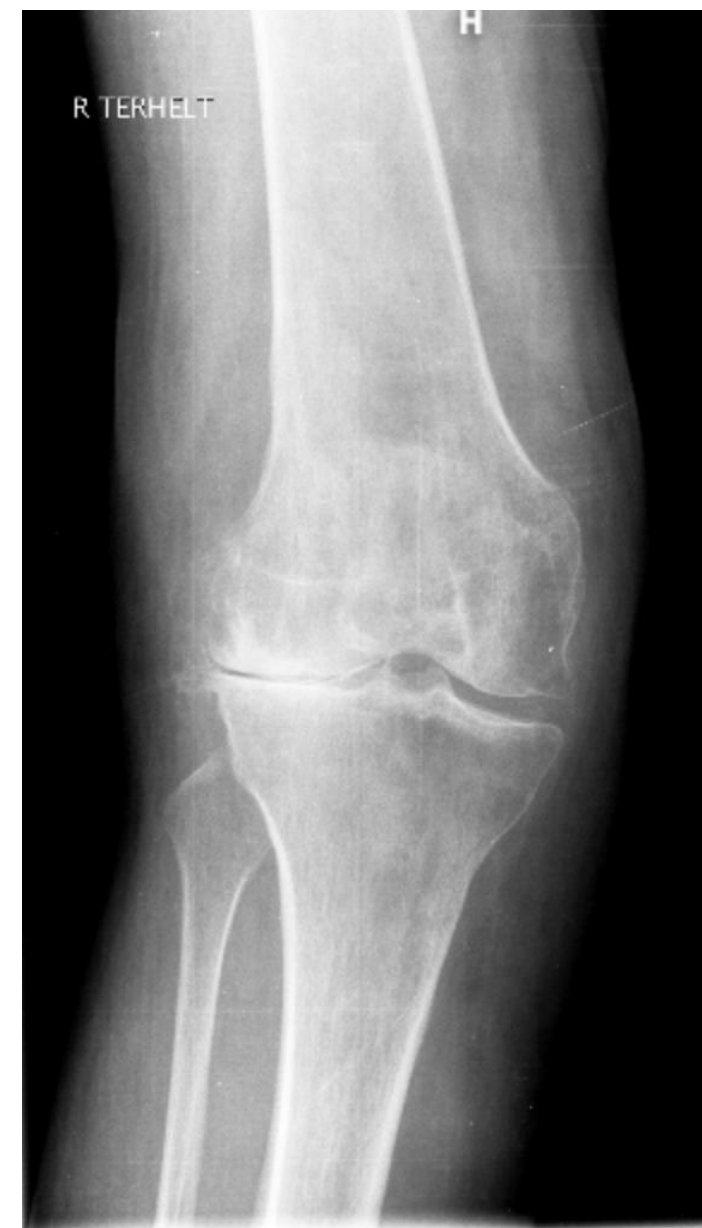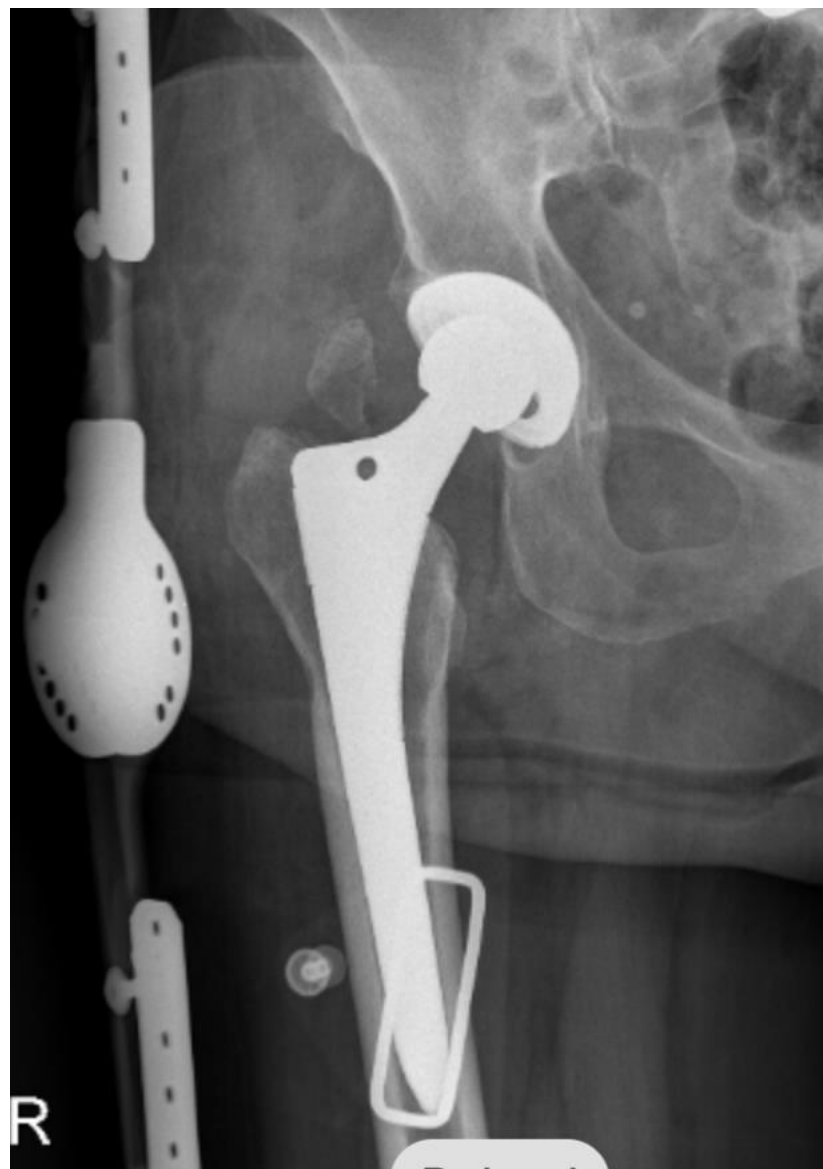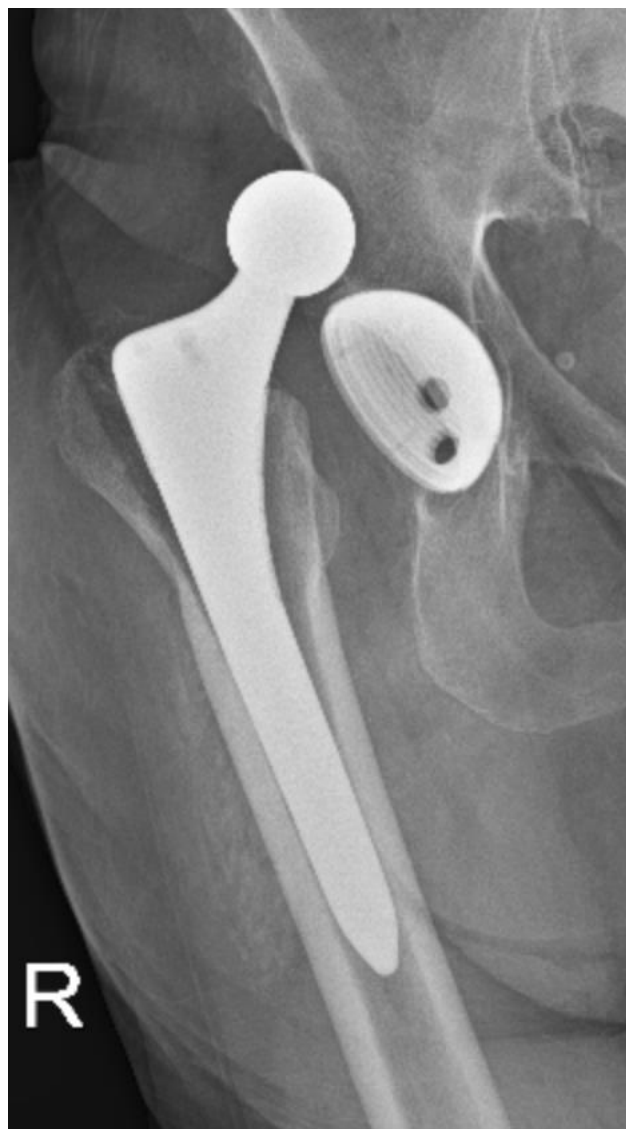preop



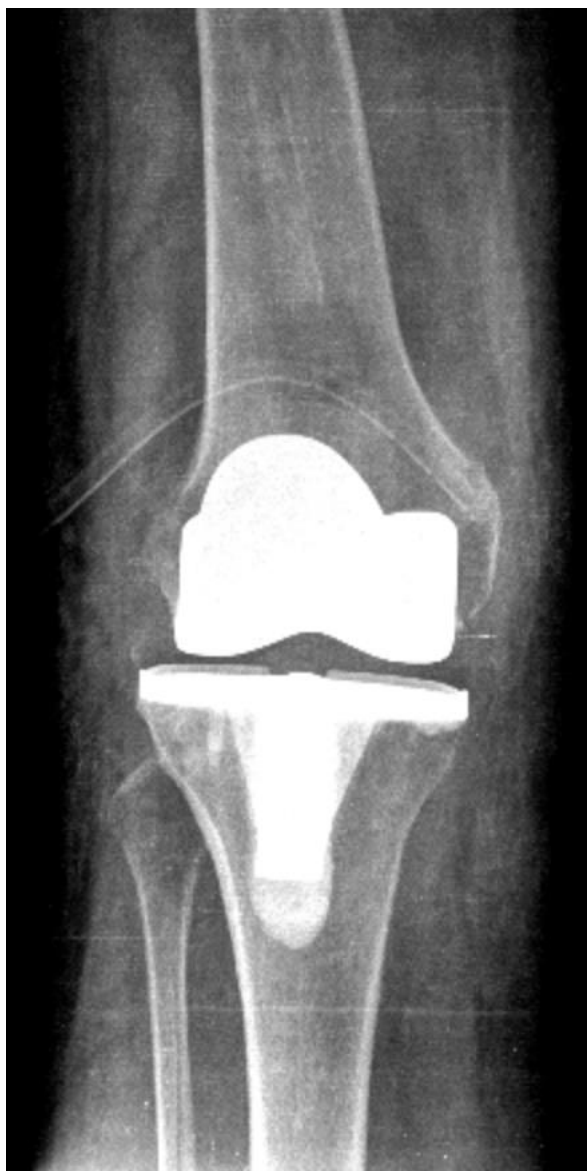2019.11.14. postop



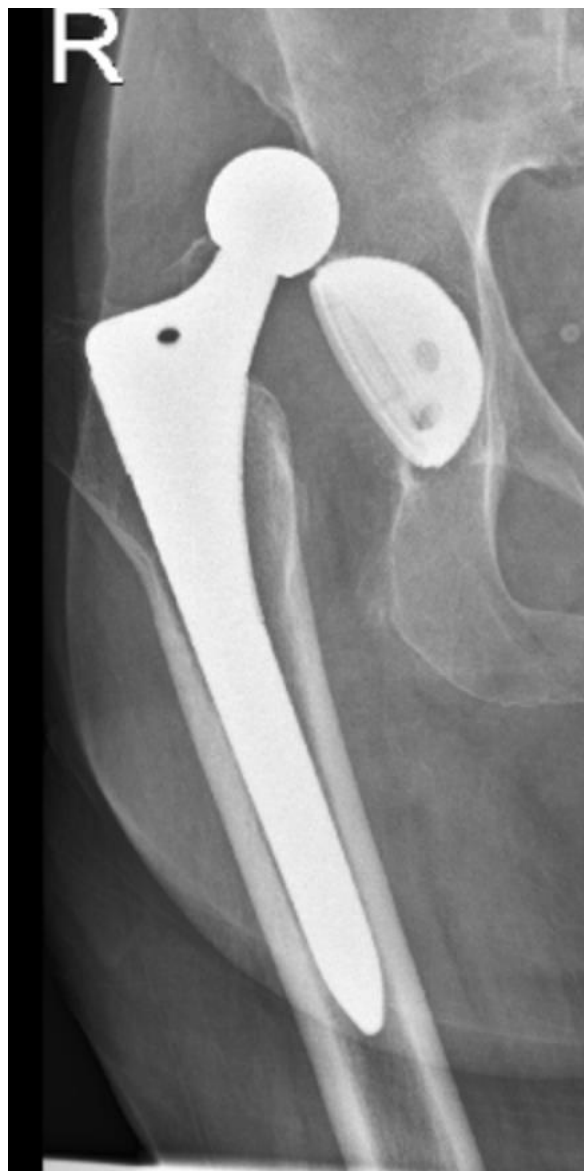2020.04.10



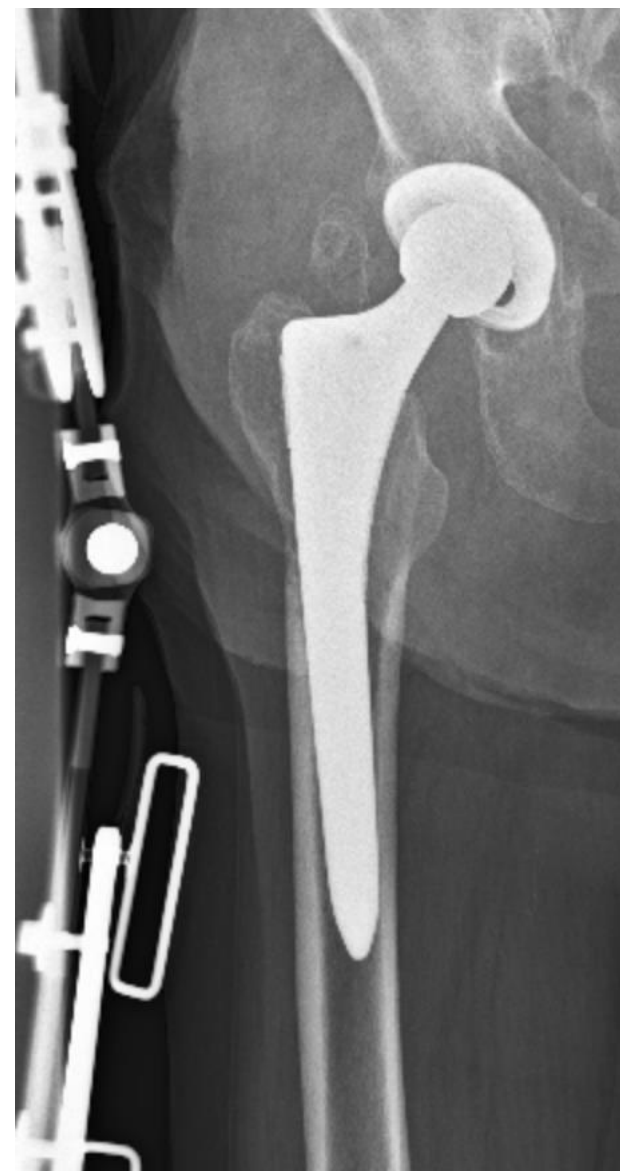2020.06.17.



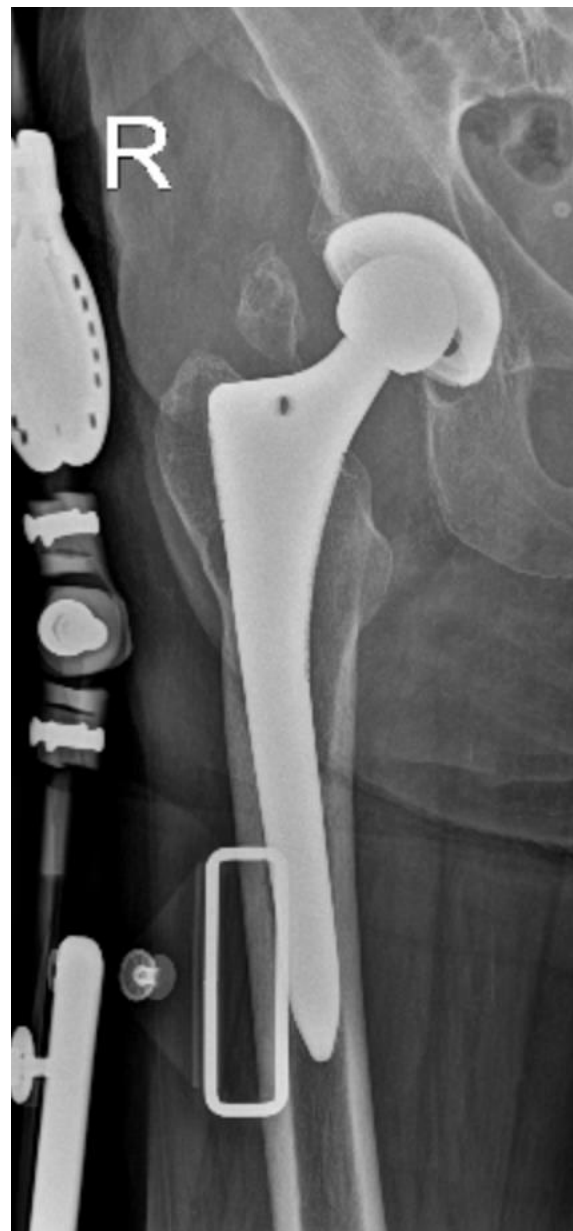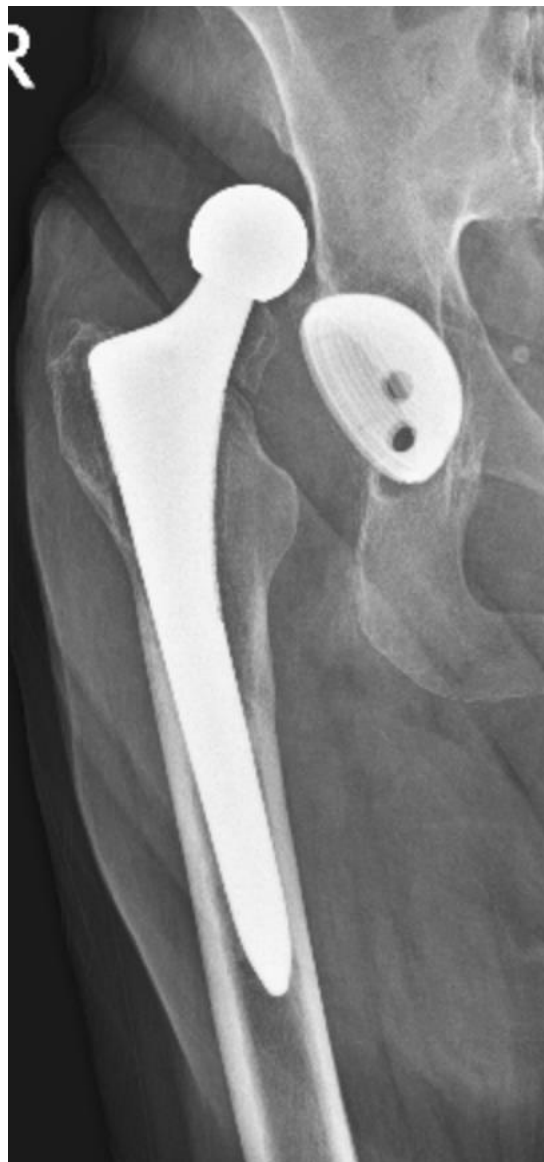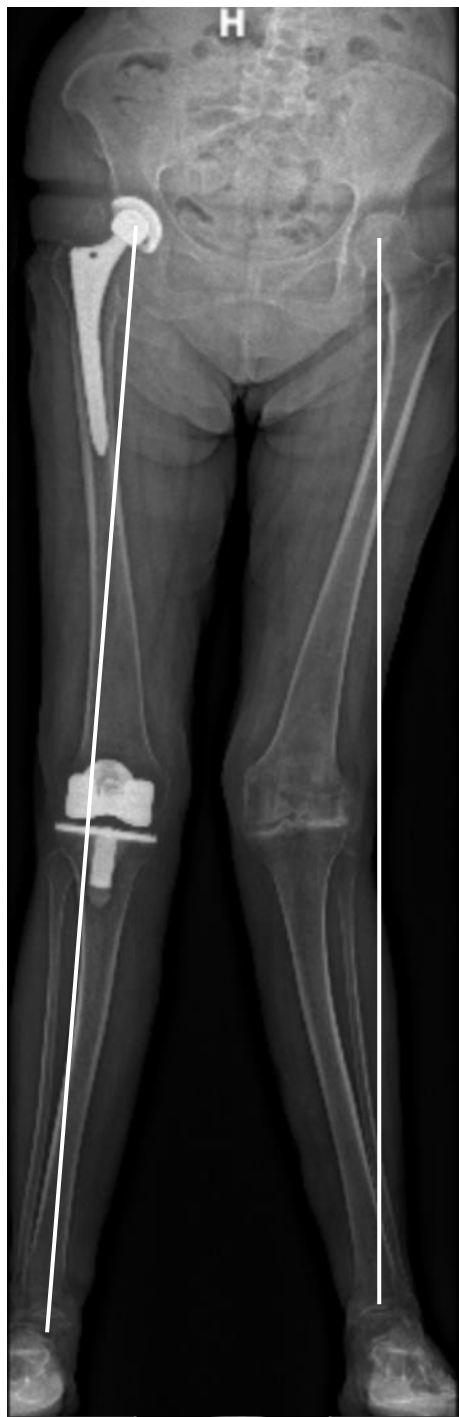2020.10.01.



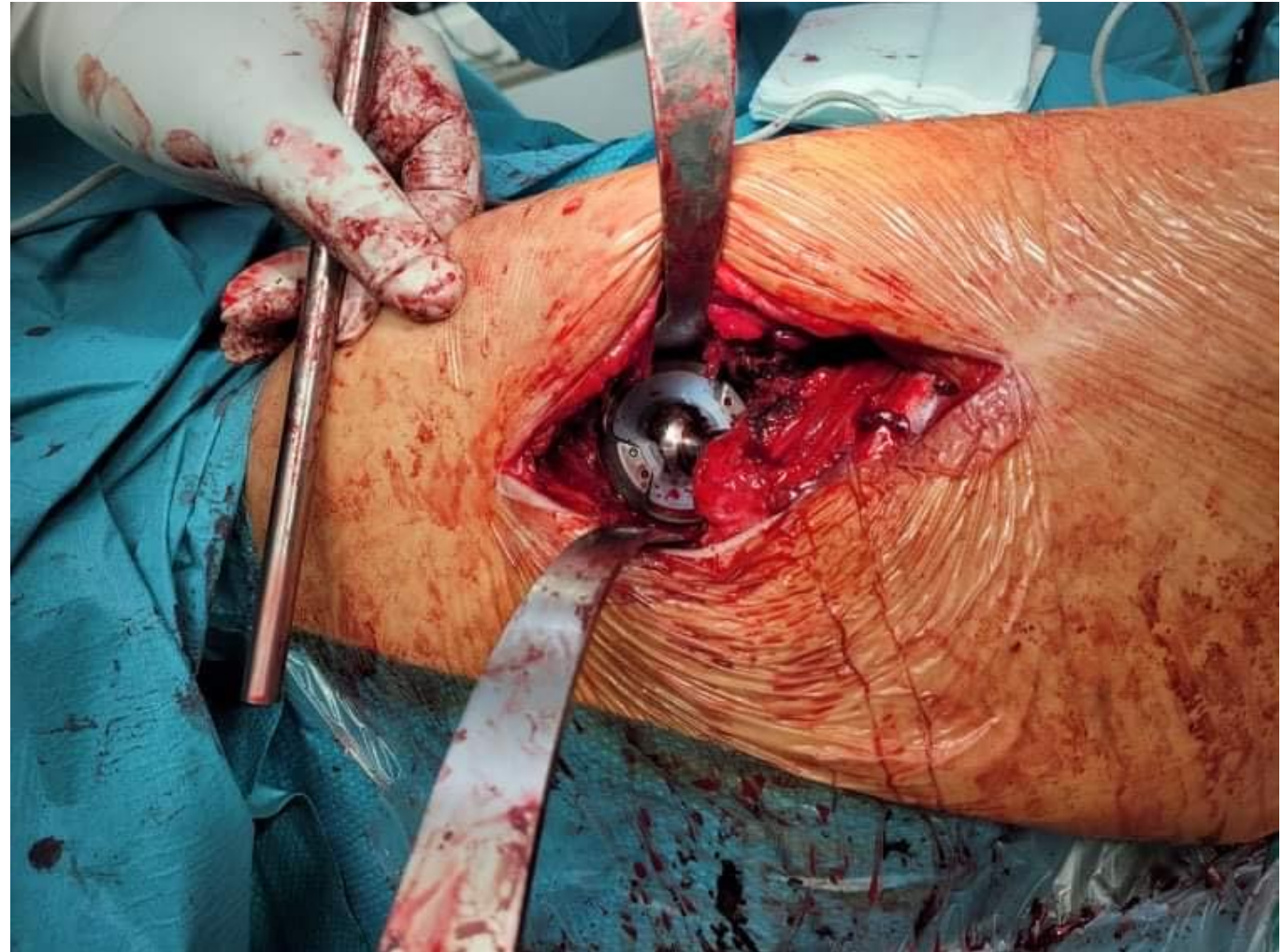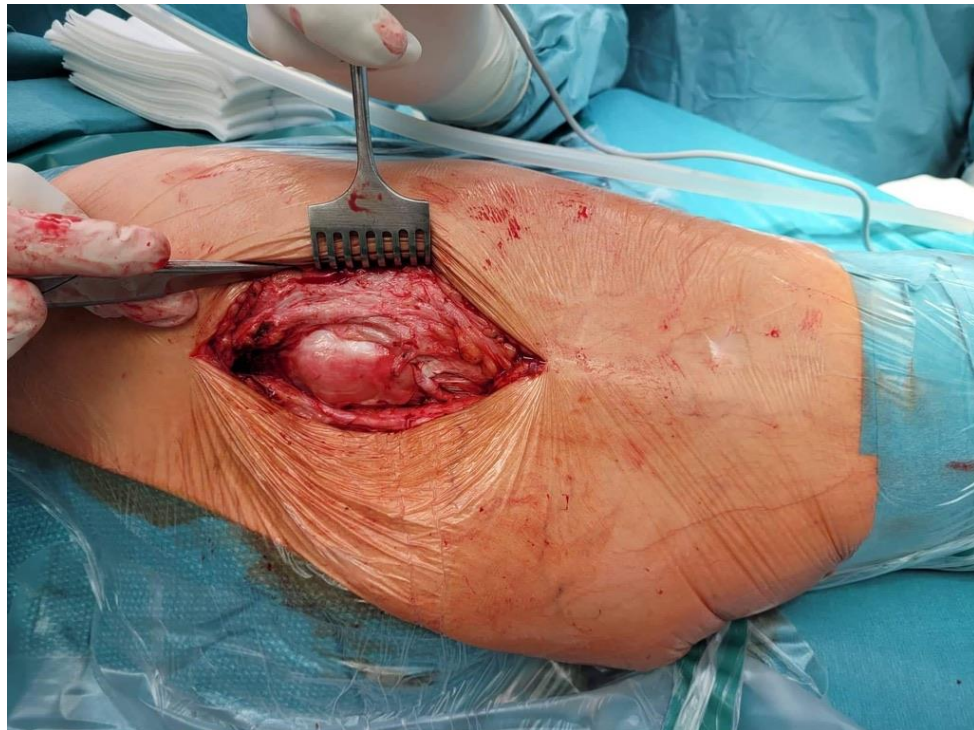
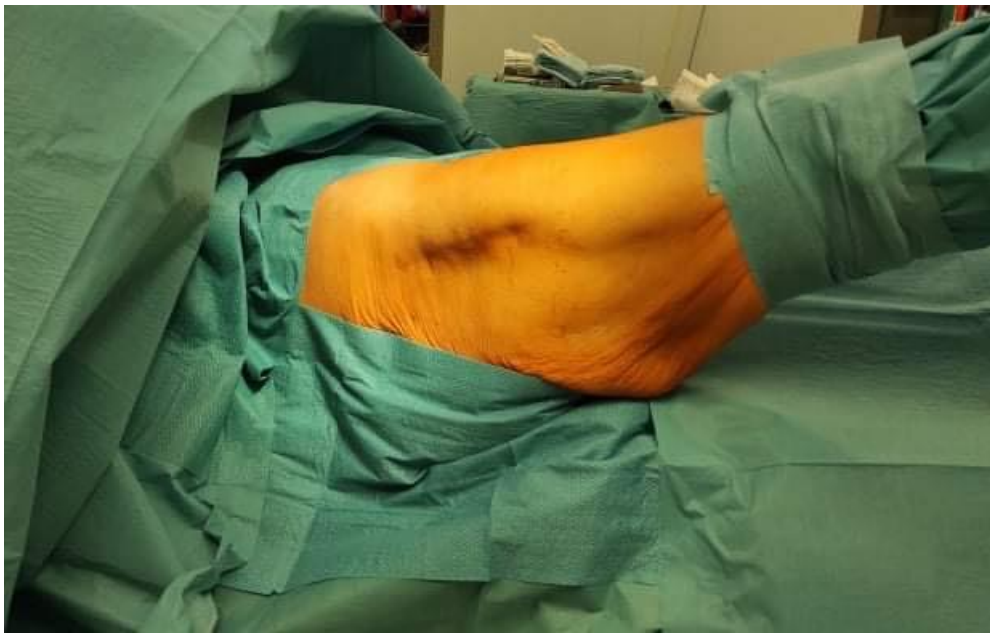2020.10.02.



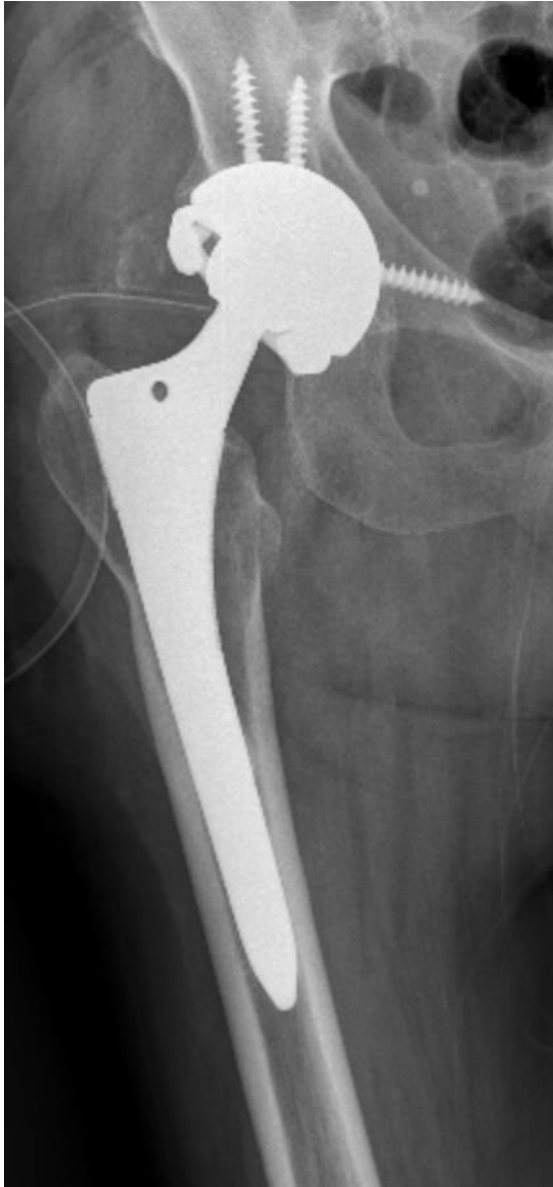2021.08.05.



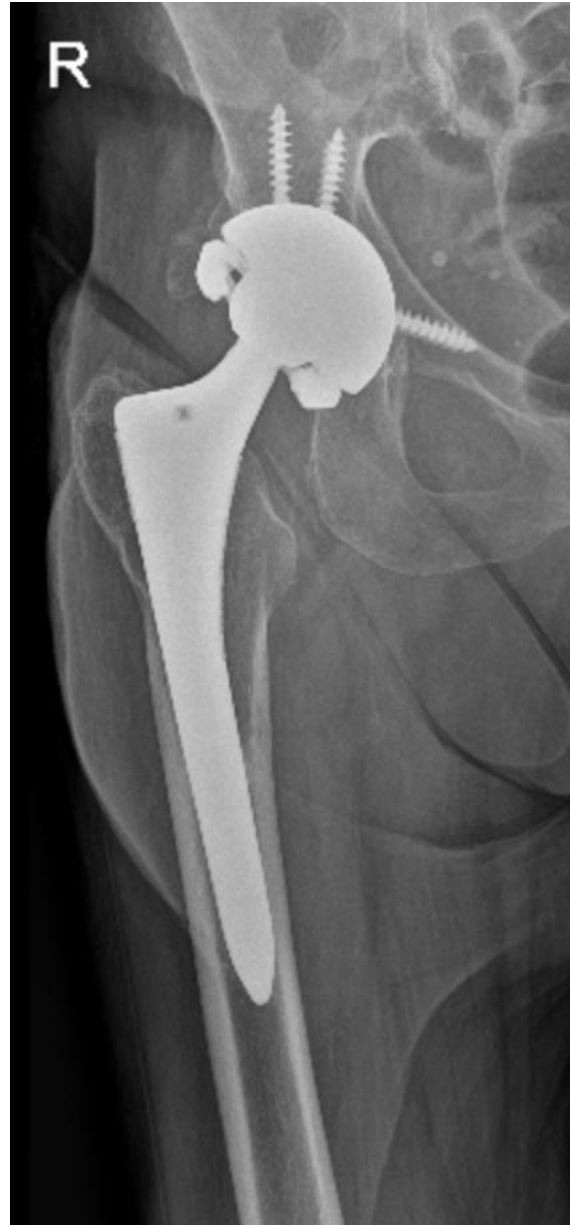
2021.10.02.



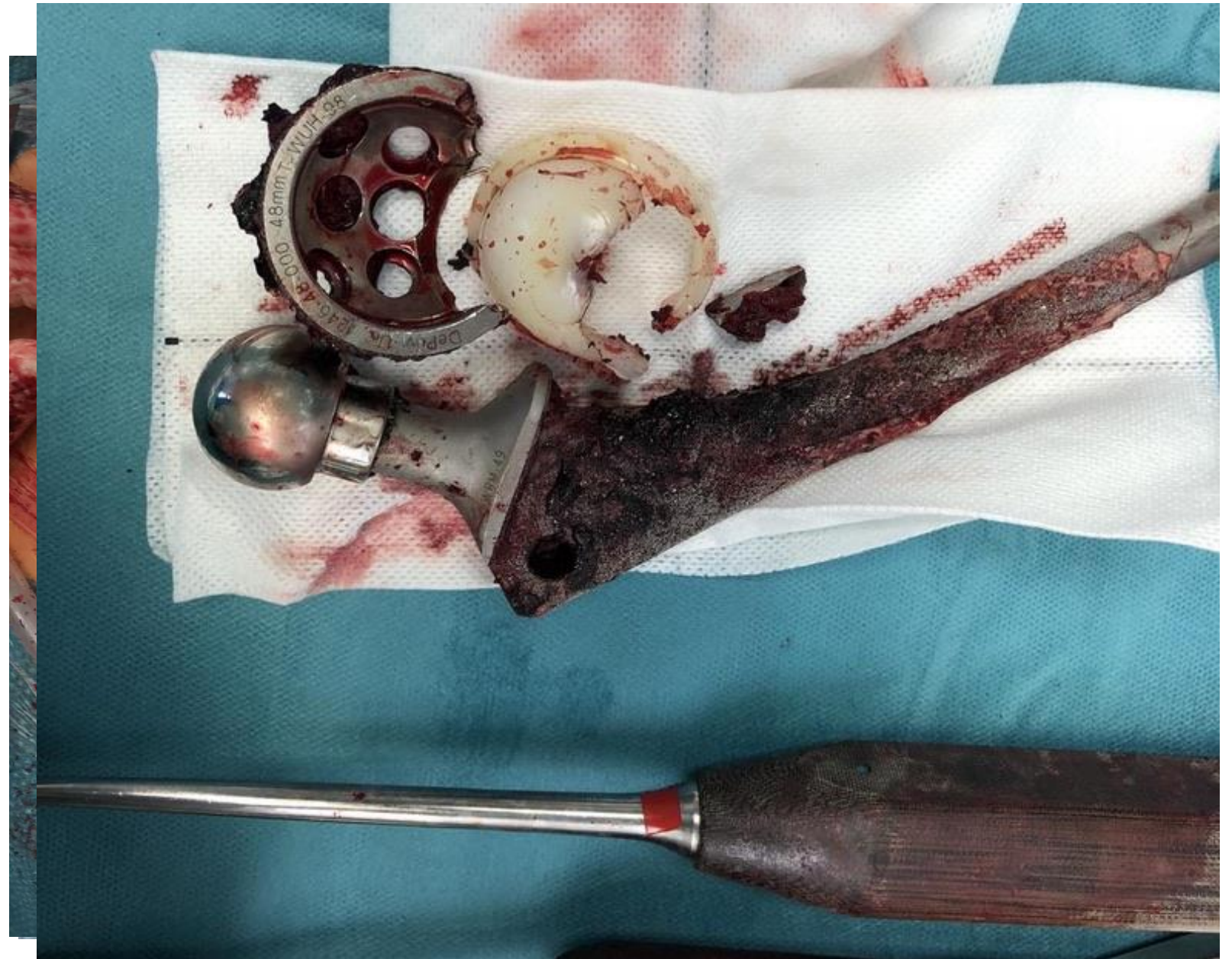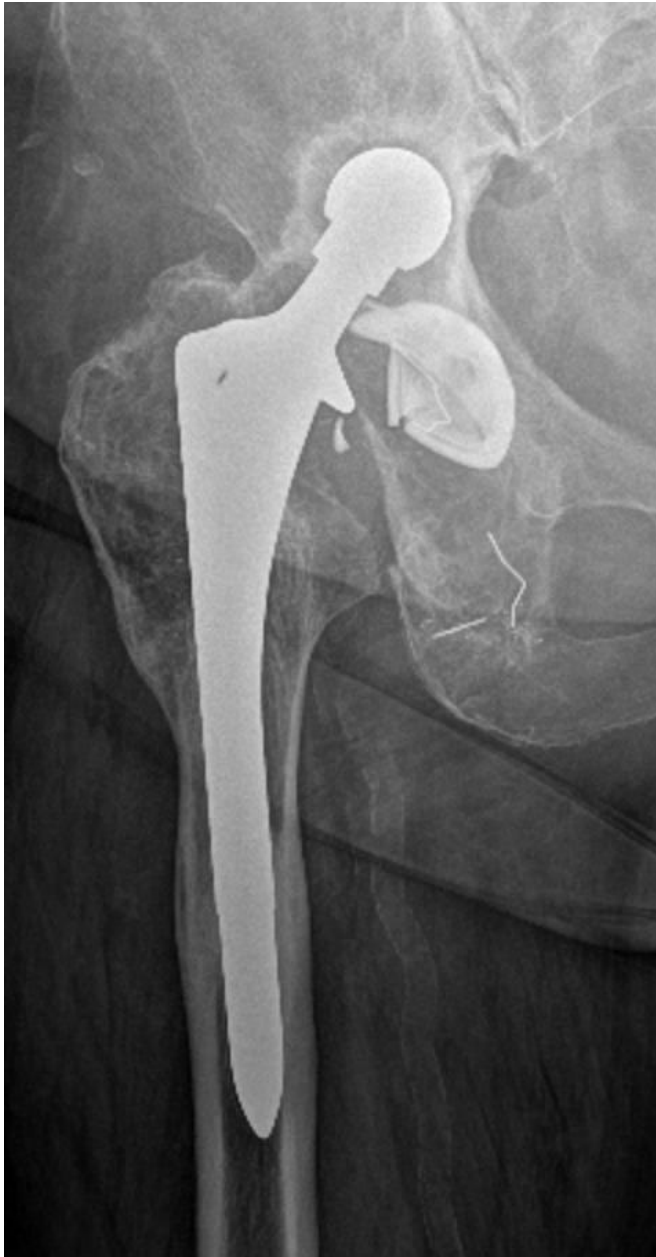2021.10.03.



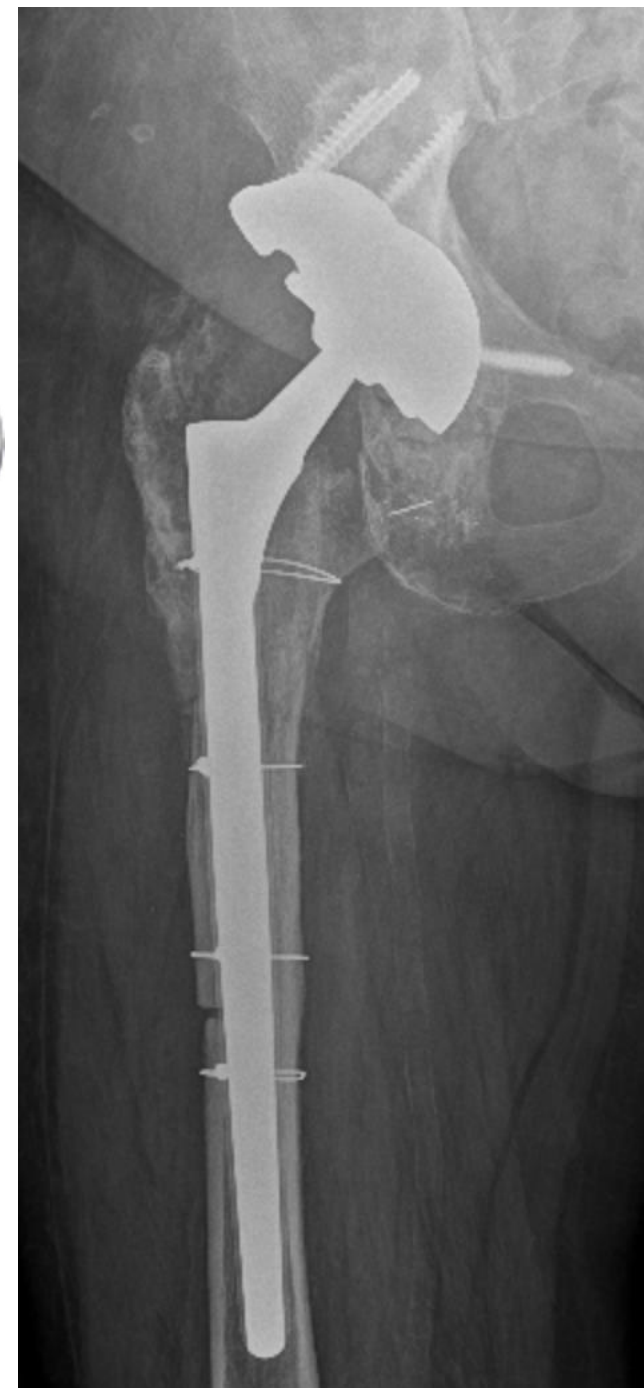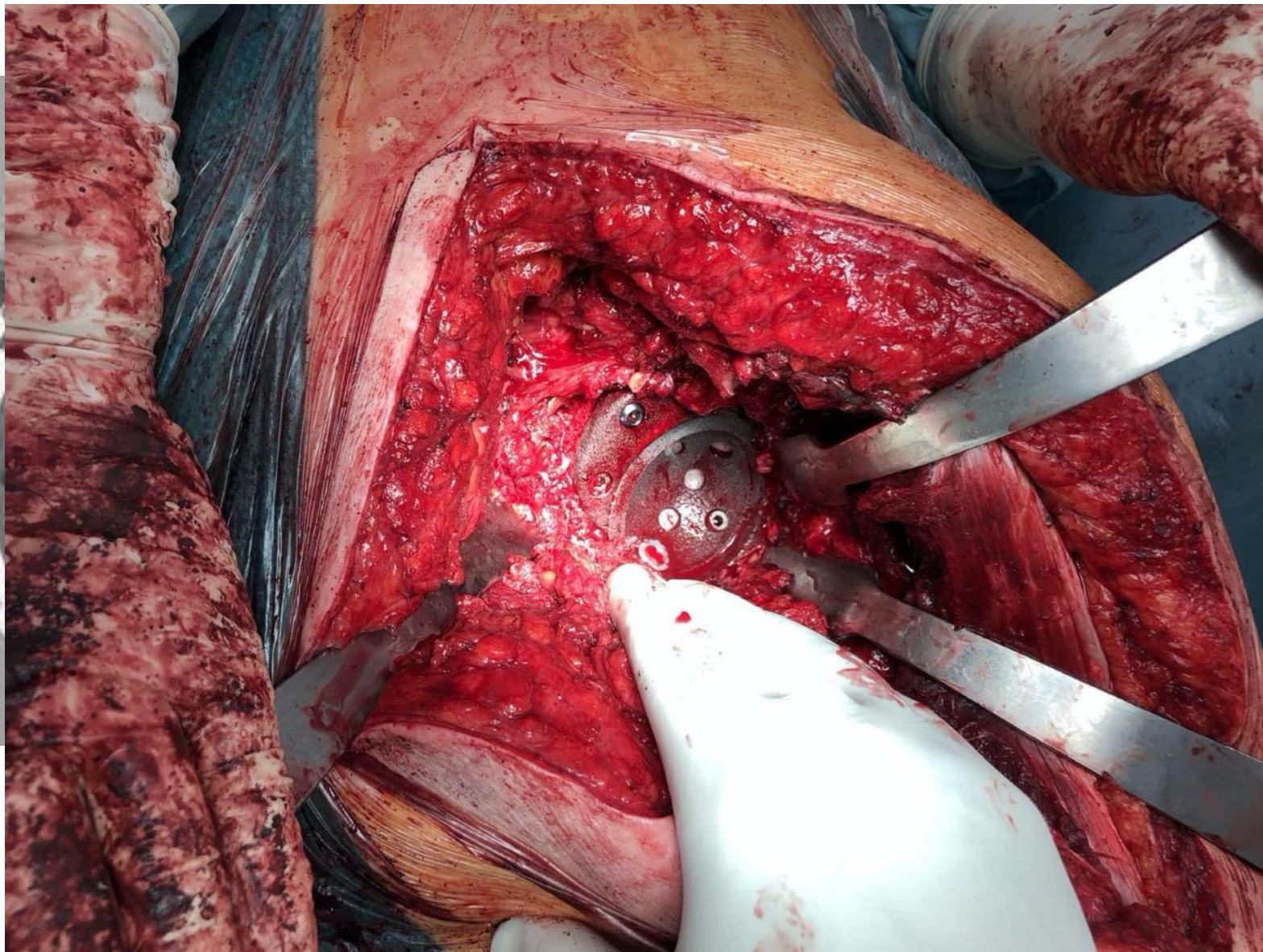
2022.05.23



64 éves nő, dysplasia, gyermekkorban műtét, 20 éves TEP, ficam???



TMARS shell+allogén csont+augment+ dual mobility vápa





KÖSZÖNÖM A FIGYELMET!

